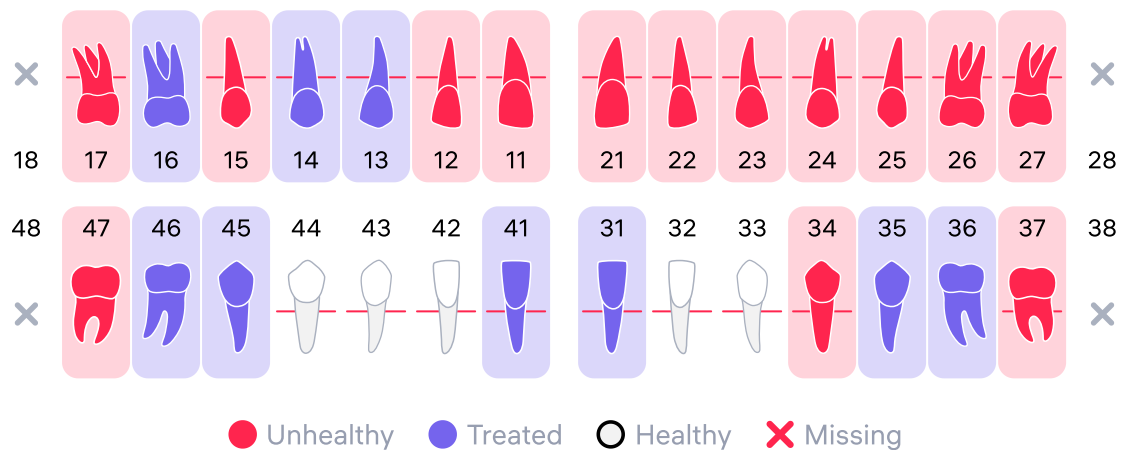
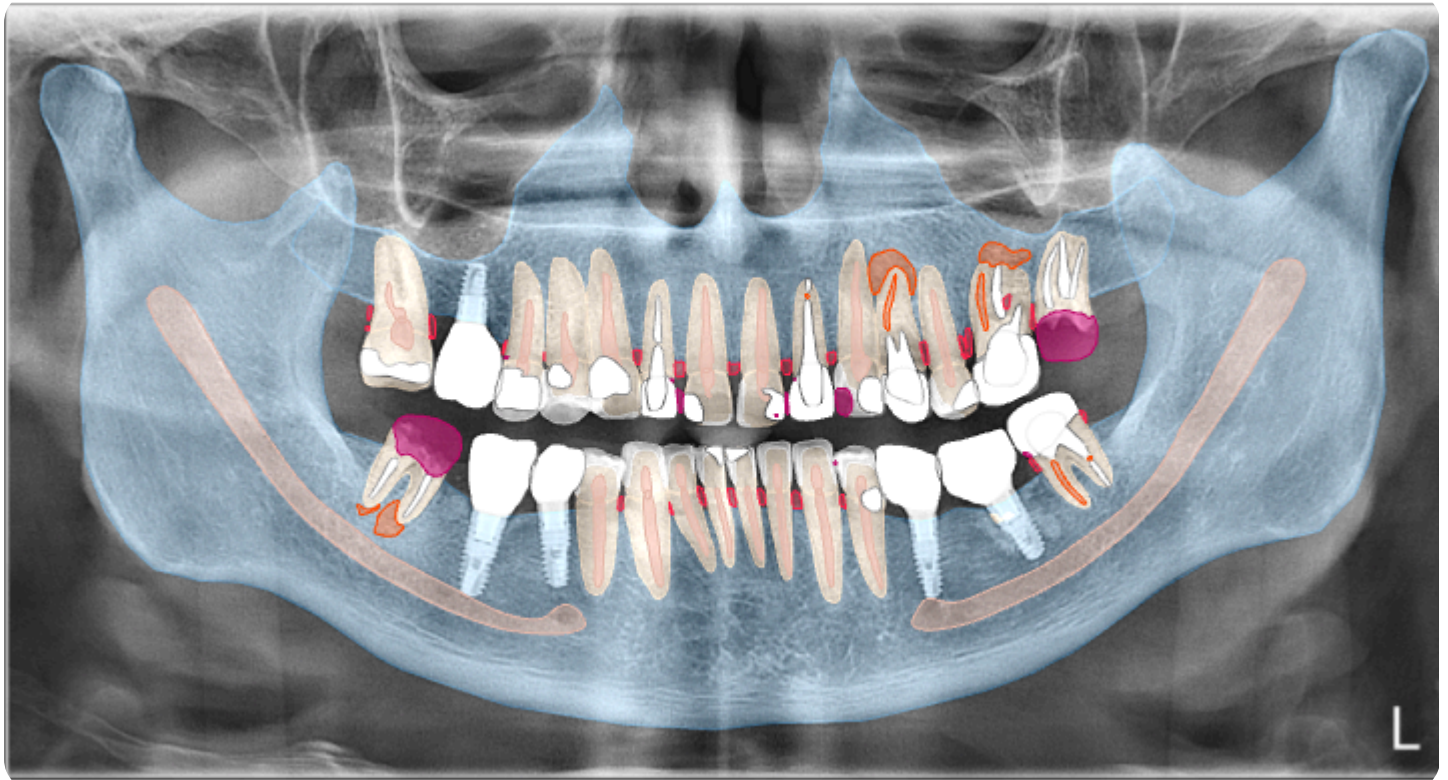
**Dental Clinic**

60313, Germany, Frankfurt am Main
Schillerstraße 33
+49 (0)69 61898293
info@DentalClinic.de

Pano AI Report


Helen Amerson DOB: September 13, 1978, 46 y.o. Study Date: Jul 21, 2025, 2:47 PM



This report contains confidential health information. It was generated with Diagnocat SaaS using Artificial Intelligence. The conditions and pathologies in this report were verified by the attending dentist.

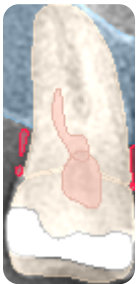Tooth 18

Missing



● Tooth 17

Tooth, Filling (Dentin, Mesial, Distal), Pulp stone, Dental calculus, Periodontal bone loss (Mild, Horizontal)



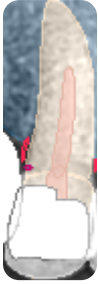
● Tooth 16

Implant, Artificial crown



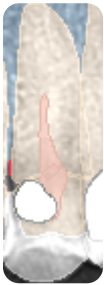● Tooth 15

Tooth, Filling (Depth is not defined, Buccal), Open margin, Periodontal bone loss (Mild, Horizontal)



● Tooth 14

Tooth, Filling (Depth is not defined, Buccal, Occlusal), Periodontal bone loss (Mild, Horizontal)



● Tooth 13

Tooth, Filling (Depth is not defined, Vestibular), Periodontal bone loss (Mild, Horizontal)




● Tooth 12

Tooth, Artificial crown, Endodontically treated tooth (Adequate obturation, Adequate density, Cast post and core), Open margin, Periodontal bone loss (Mild, Horizontal)



● Tooth 11

Tooth, Filling (Dentin, Distal, Incisal edge), Lack of the interproximal contact, Periodontal bone loss (Mild, Vertical, Horizontal)



● Tooth 21

Tooth, Filling (Dentin, Distal, Incisal edge), Periodontal bone loss (Mild, Vertical, Horizontal), Voids in the filling



● Tooth 22

Tooth, Artificial crown, Endodontically treated tooth (Adequate obturation, Voids present in the root filling, Cast post and core), Open margin, Lack of the interproximal contact, Periodontal bone loss (Mild, Horizontal)



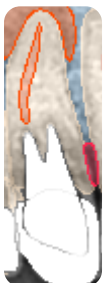● Tooth 23

Tooth, Filling (Dentin, Distal, Incisal edge), Caries signs (Dentin, Mesial, Lingual, Vestibular, Incisal edge), Periodontal bone loss (Mild, Horizontal)



● Tooth 24

Tooth, Artificial crown, Endodontically treated tooth (Missed canal, Cast post and core), Periodontal bone loss (Mild, Horizontal), Periapical radiolucency



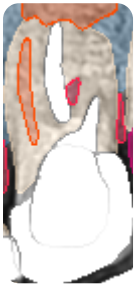● Tooth 25

Tooth, Filling (Dentin, Distal, Occlusal), Dental calculus, Periodontal bone loss (Mild, Horizontal, Mixed)



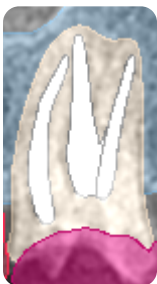
● Tooth 26

Tooth, Artificial crown, Endodontically treated tooth (Missed canal, Cast post and core), Furcation lesion, Periodontal bone loss (Mild, Horizontal, Mixed), Periapical radiolucency




● Tooth 27

Tooth, Caries signs (Dentin, Mesial, Distal, Lingual, Buccal), Endodontically treated tooth (Adequate obturation, Adequate density), Periodontal bone loss (Mild, Horizontal)




Tooth 28

Missing



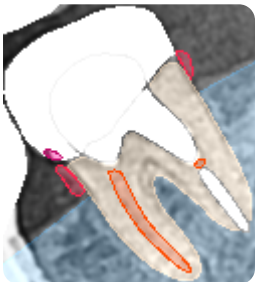
Tooth 38

Missing



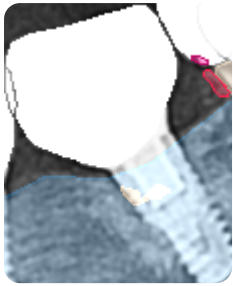
● Tooth 37

Tooth, Artificial crown, Endodontically treated tooth (Missed canal, Voids present in the root filling, Cast post and core), Overhang, Periodontal bone loss (Mild, Horizontal)




● Tooth 36

Implant, Artificial crown



● Tooth 35

Implant, Artificial crown



● Tooth 34

Tooth, Filling (Depth is not defined, Buccal), Caries signs (Enamel, Mesial), Periodontal bone loss (Mild, Horizontal)



○ Tooth 33

Tooth, Periodontal bone loss (Mild, Horizontal)



○ Tooth 32

Tooth, Periodontal bone loss (Mild, Horizontal)



● Tooth 31

Tooth, Filling (Dentin, Mesial, Distal, Incisal edge), Periodontal bone loss (Mild, Horizontal)



● Tooth 41

Tooth, Filling (Dentin, Mesial, Incisal edge), Periodontal bone loss (Mild, Horizontal)



○ Tooth 42

Tooth, Periodontal bone loss (Mild, Horizontal)



○ Tooth 43

Tooth, Periodontal bone loss (Mild, Horizontal)



○ Tooth 44

Tooth, Periodontal bone loss (Mild, Horizontal)



● Tooth 45

Implant, Artificial crown



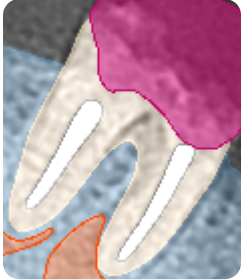
● Tooth 46

Implant, Artificial crown




● Tooth 47

Tooth, Caries signs (Dentin, Mesial, Distal, Lingual, Buccal),
Endodontically treated tooth (Adequate obturation, Adequate density),
Periapical radiolucency



Tooth 48

Missing



Report signed: Jul 21, 2025, 3:39 PM



Dr. David Johnston
Dental Clinic
Schillerstraße 33
60313 Frankfurt am Main
+49 (0)69 61898293



Johnston David

Chief Dental Officer