
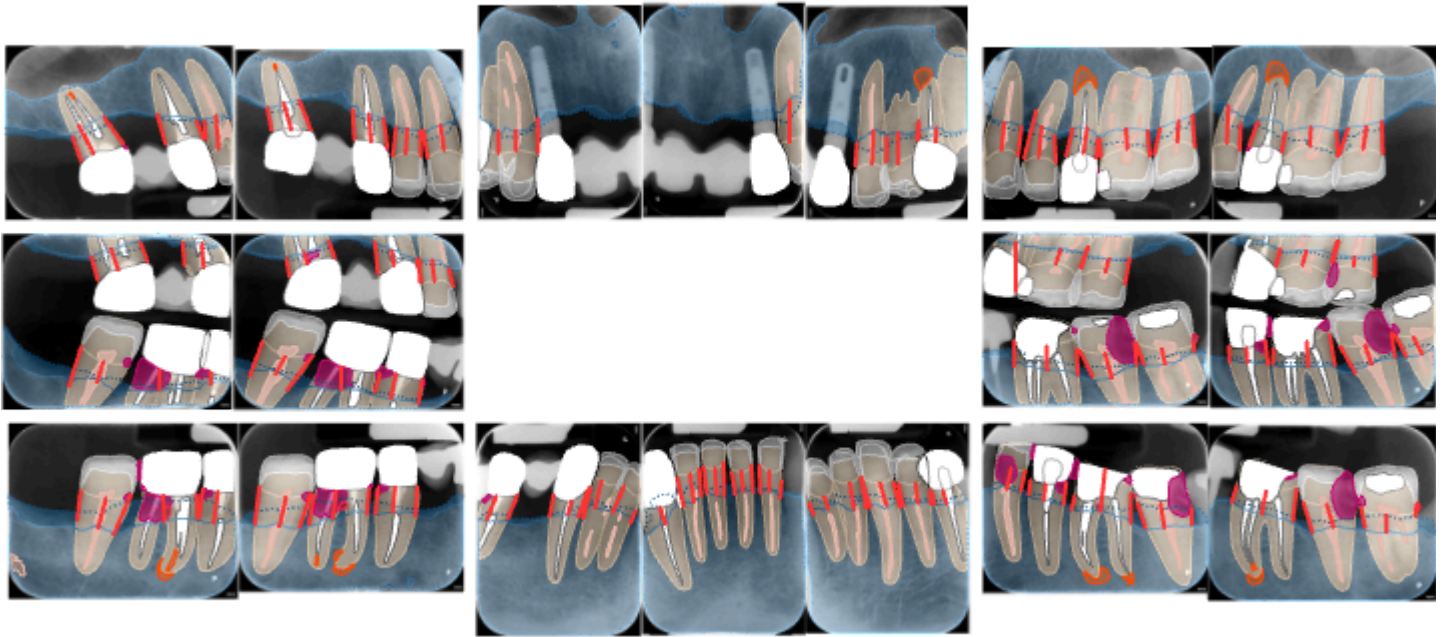
**Dental Clinic**

60313, Germany, Frankfurt am Main  
Schillerstraße 33  
+49 (0)69 61898293  
info@DentalClinic.de

# IOXRay AI Report

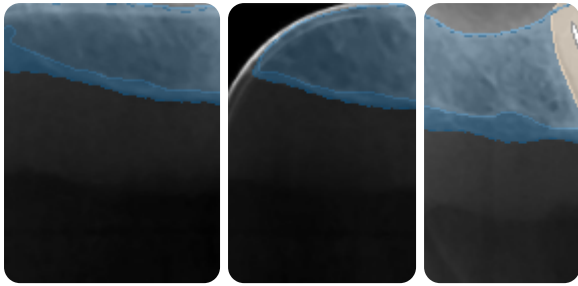
Felecia Hall DOB: July 8, 1971, 54 y.o. Study Date: Jul 21, 2025, 3:41 PM



This report contains confidential health information. It was generated with Diagnocat SaaS using Artificial Intelligence. The conditions and pathologies in this report were verified by the attending dentist.

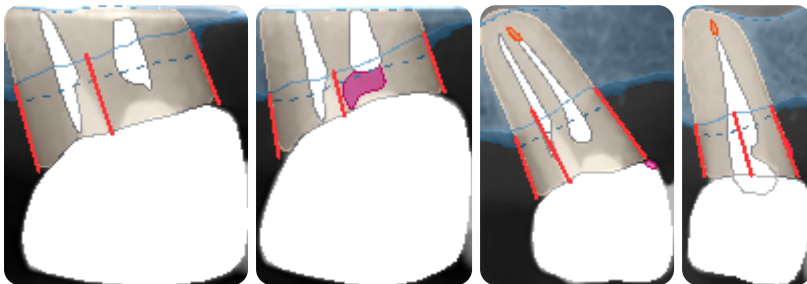
## Tooth 18

Missing



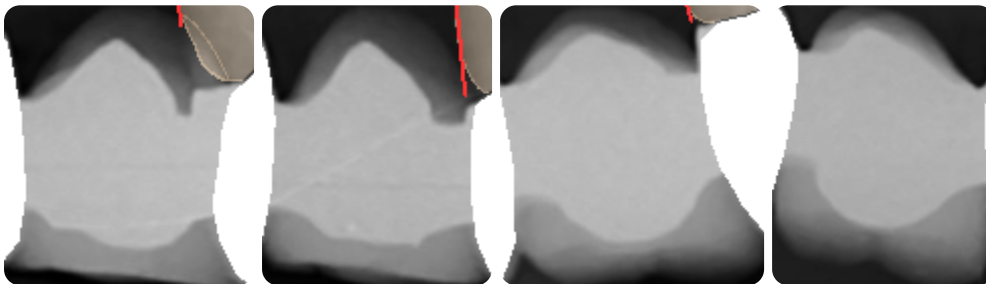
## ● Tooth 17

Tooth, Artificial crown, Endodontically treated tooth (Short filling), Dental calculus, Overhang, Periodontal bone loss, Voids in the filling



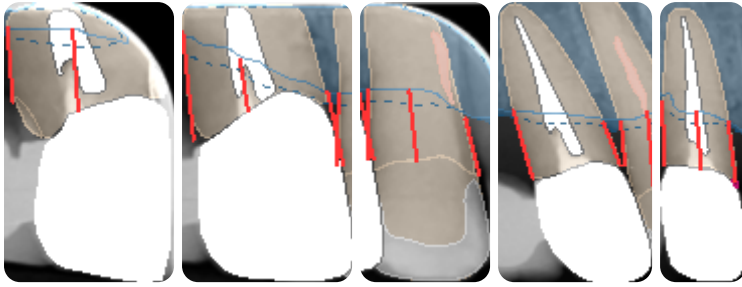
## ● Tooth 16

Pontic



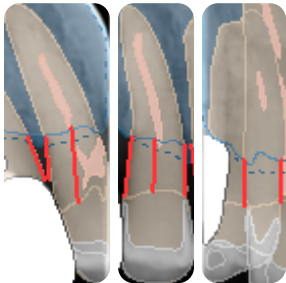
## ● Tooth 15

Tooth, Artificial crown, Endodontically treated tooth, Open margin, Periodontal bone loss



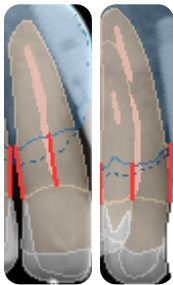
## ● Tooth 14

Tooth, Artificial crown, Periodontal bone loss



## ○ Tooth 13

Tooth, Periodontal bone loss



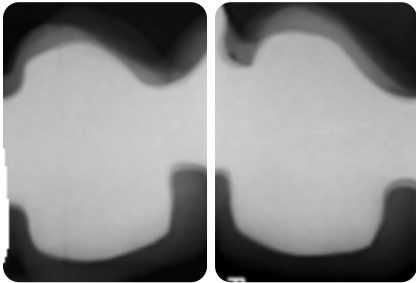
## ● Tooth 12

Implant, Artificial crown



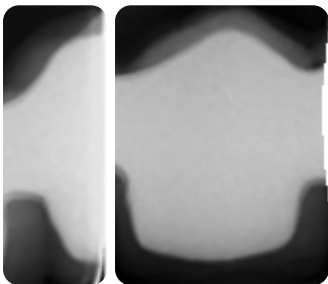
## ● Tooth 11

Pontic



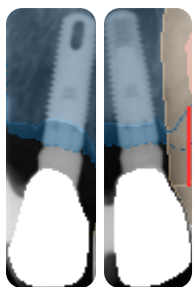
## ● Tooth 21

Pontic



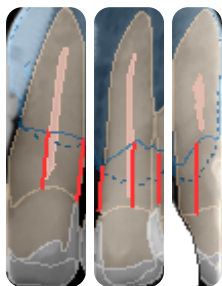
## ● Tooth 22

Implant, Artificial crown



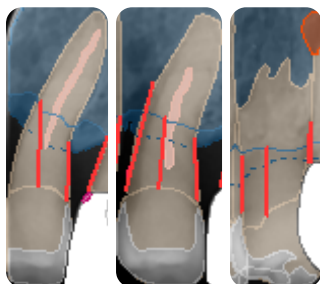
## ○ Tooth 23

Tooth, Periodontal bone loss



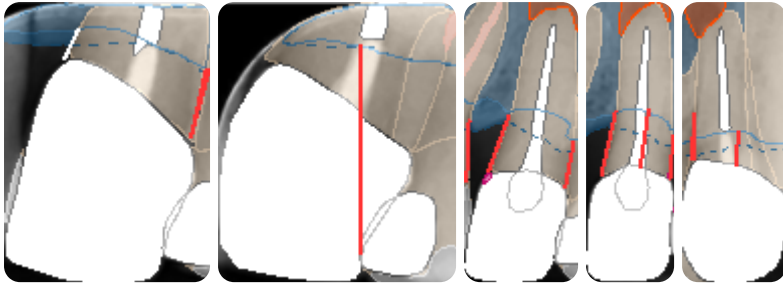
## ● Tooth 24

Tooth, Dental calculus, Periodontal bone loss



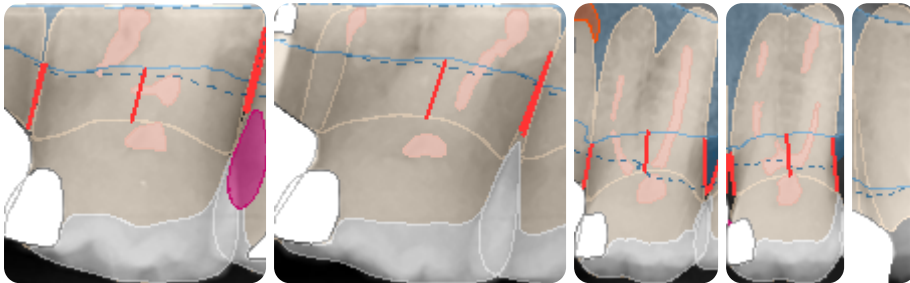
## ● Tooth 25

Tooth, Artificial crown, Endodontically treated tooth, Open margin, Overhang, Periodontal bone loss, Periapical radiolucency



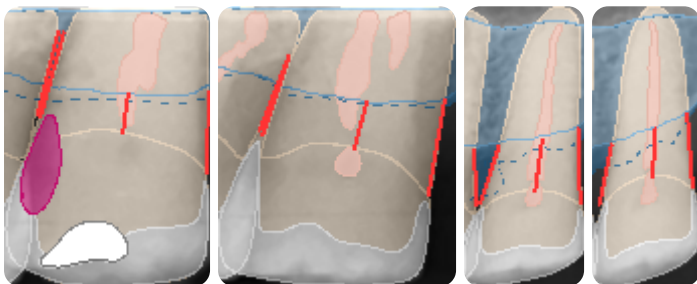
## ● Tooth 26

Tooth, Filling, Overhang, Periodontal bone loss



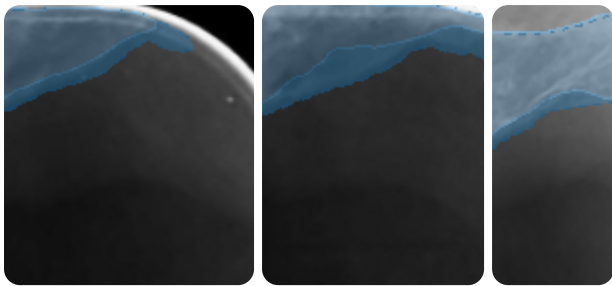
## ● Tooth 27

Tooth, Filling, Caries signs, Periodontal bone loss



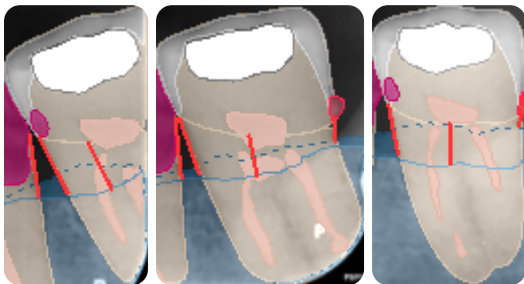
## Tooth 28

Missing



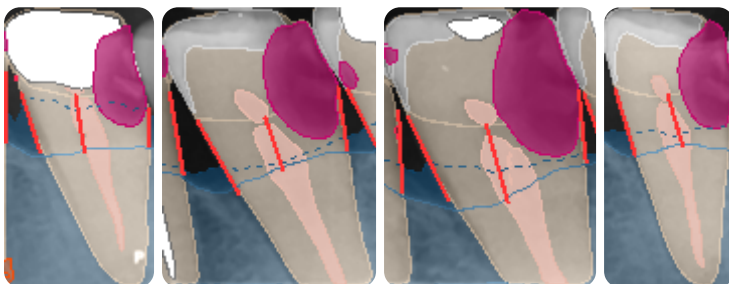
## ● Tooth 38

Tooth, Filling, Caries signs, Dental calculus, Periodontal bone loss



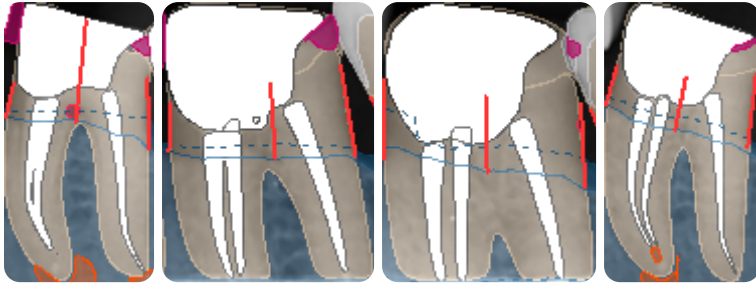
## ● Tooth 37

Tooth, Filling, Caries signs, Dental calculus, Periodontal bone loss



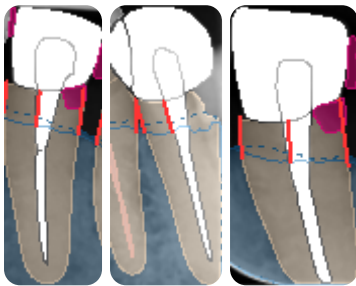
## ● Tooth 36

Tooth, Filling, Endodontically treated tooth (Short filling), Furcation lesion, Dental calculus, Lack of the interproximal contact, Secondary caries, Periodontal bone loss, Periapical radiolucency



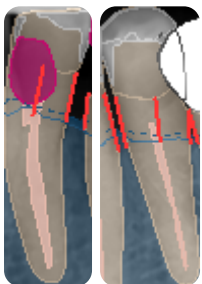
## ● Tooth 35

Tooth, Artificial crown, Endodontically treated tooth, Lack of the interproximal contact, Secondary caries, Periodontal bone loss



## ● Tooth 34

Tooth, Filling, Caries signs, Lack of the interproximal contact, Periodontal bone loss





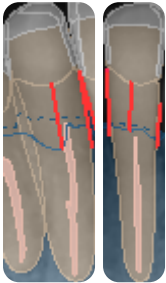## ○ Tooth 33

Tooth, Periodontal bone loss



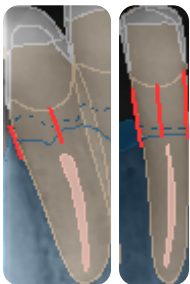
## ● Tooth 32

Tooth, Dental calculus, Periodontal bone loss



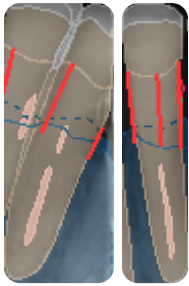
## ○ Tooth 31

Tooth, Periodontal bone loss



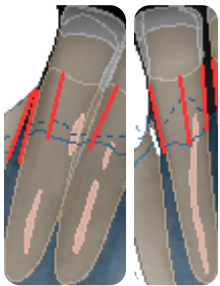
## ● Tooth 41

Tooth, Dental calculus, Periodontal bone loss



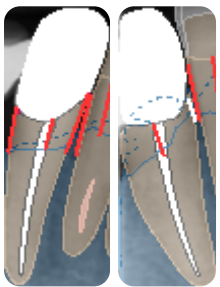
## ● Tooth 42

Tooth, Dental calculus, Periodontal bone loss



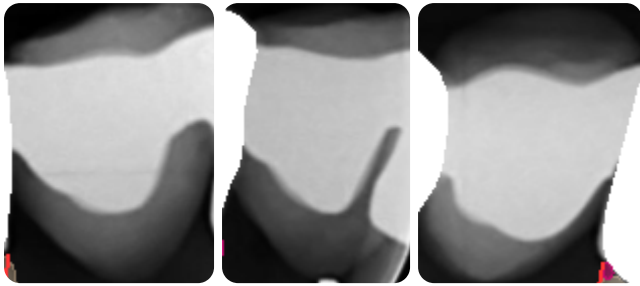
## ● Tooth 43

Tooth, Artificial crown, Endodontically treated tooth, Open margin, Periodontal bone loss



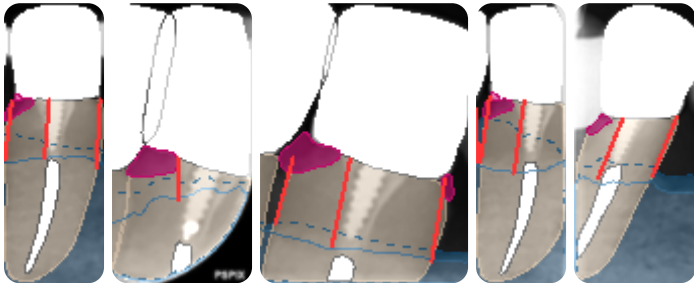
## ● Tooth 44

Pontic



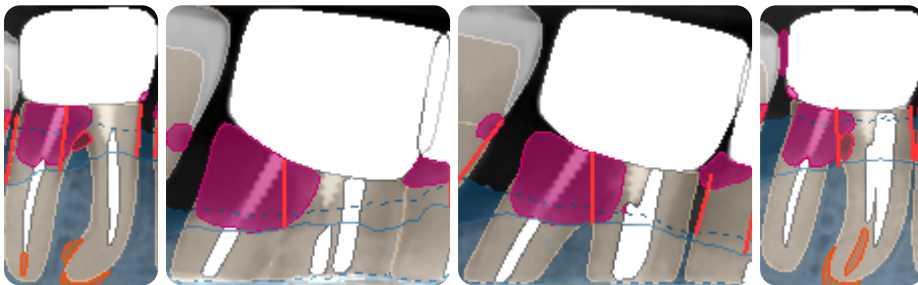
## ● Tooth 45

Tooth, Artificial crown, Endodontically treated tooth, Open margin, Overhang, Secondary caries, Periodontal bone loss



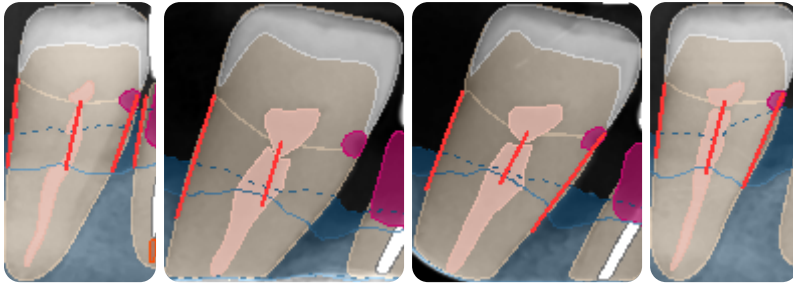
## ● Tooth 46

Tooth, Artificial crown, Endodontically treated tooth (Short filling), Furcation lesion, Overhang, Lack of the interproximal contact, Secondary caries, Periodontal bone loss, Periapical radiolucency



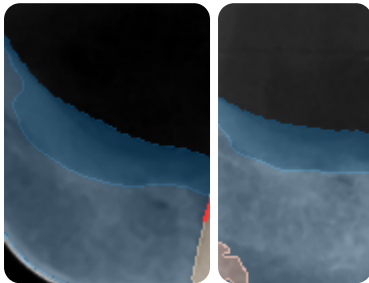
## ● Tooth 47

Tooth, Caries signs, Dental calculus, Lack of the interproximal contact, Periodontal bone loss



## Tooth 48

Missing



Report signed: Jul 21, 2025, 4:02 PM



**Dr. David Johnston**  
Dental Clinic  
Schillerstraße 33  
60313 Frankfurt am Main  
+49 (0)69 61898293



**Johnston David**

Chief Dental Officer