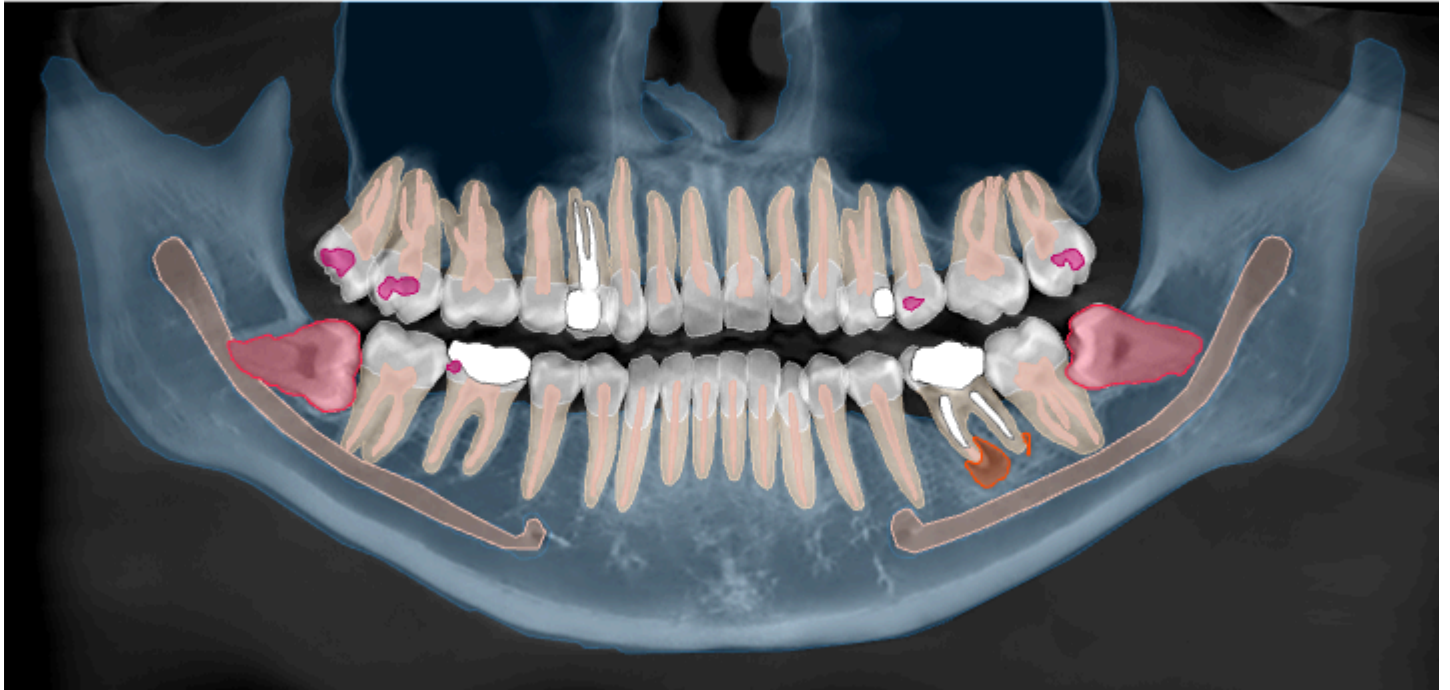
**Dental Clinic**

60313, Germany, Frankfurt am Main
Schillerstraße 33
+49 (0)69 61898293
info@DentalClinic.de

CBCT AI Report

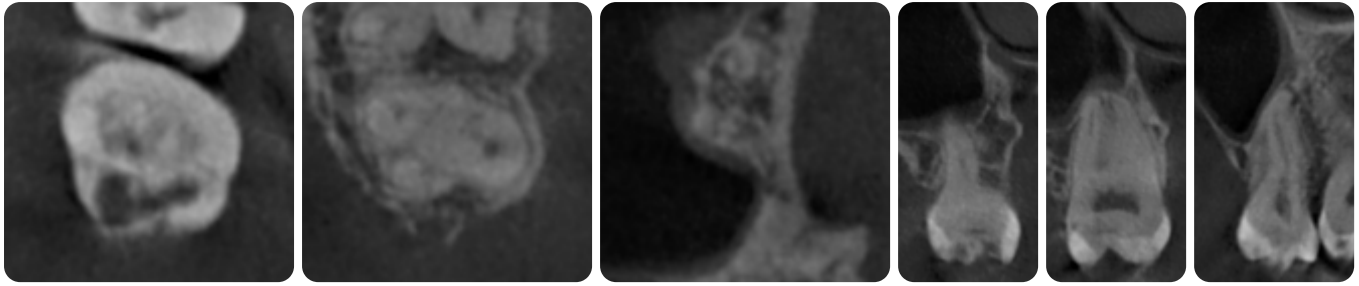
Stacey Patterson DOB: December 18, 1980, 44 y.o. Study Date: Sep 18, 2023, 10:38 AM



This report contains confidential health information. It was generated with Diagnocat SaaS using Artificial Intelligence. The conditions and pathologies in this report were verified by the attending dentist.

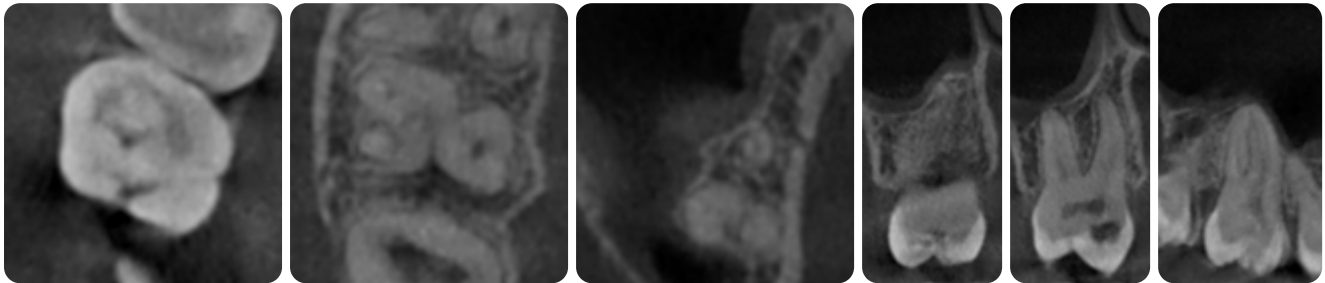
● Tooth 18

Tooth, 3 roots, 4 canals, Caries signs (Dentin, Buccal, Occlusal)



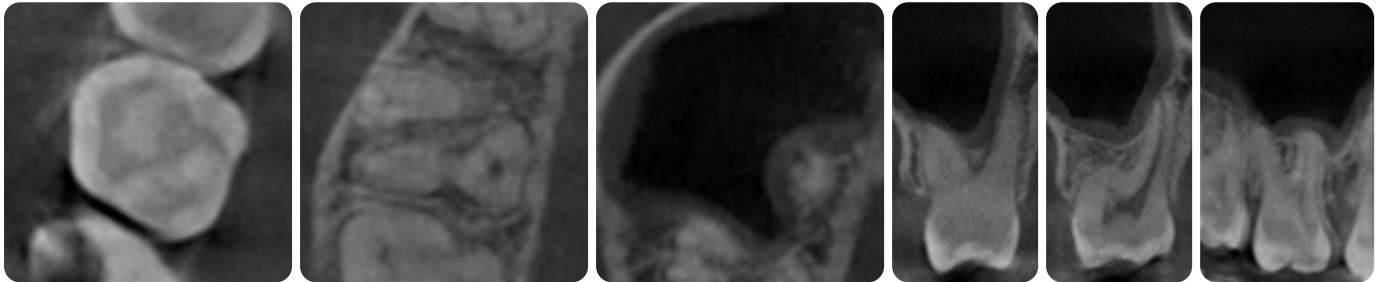
● Tooth 17

Tooth, 3 roots, 4 canals, Caries signs (Dentin, Occlusal)



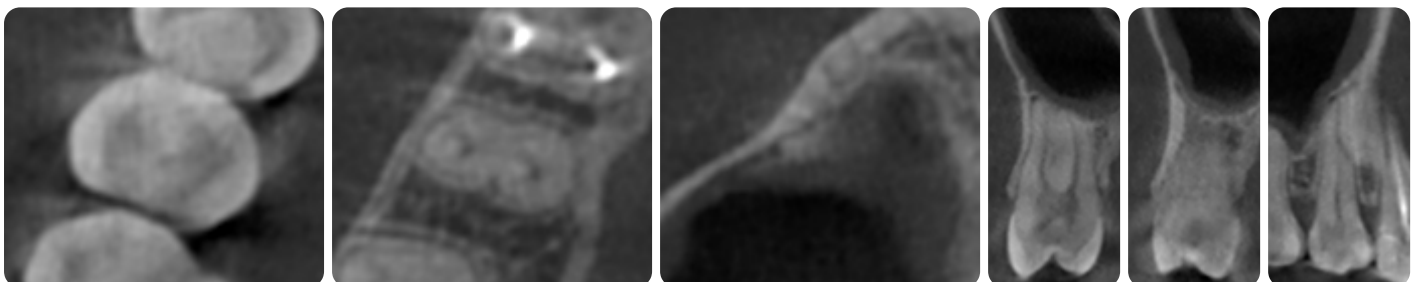
● Tooth 16

Tooth, Filling, 3 roots, 4 canals, Pulp stone



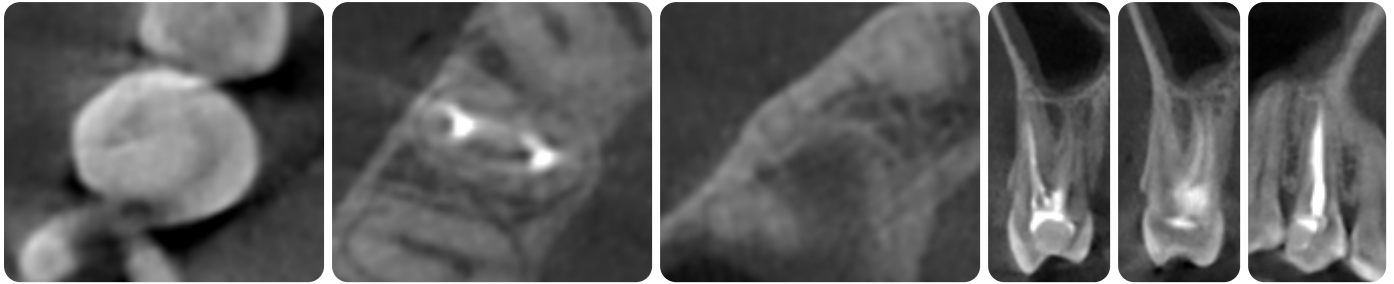
○ Tooth 15

Tooth, 1 root, 2 canals



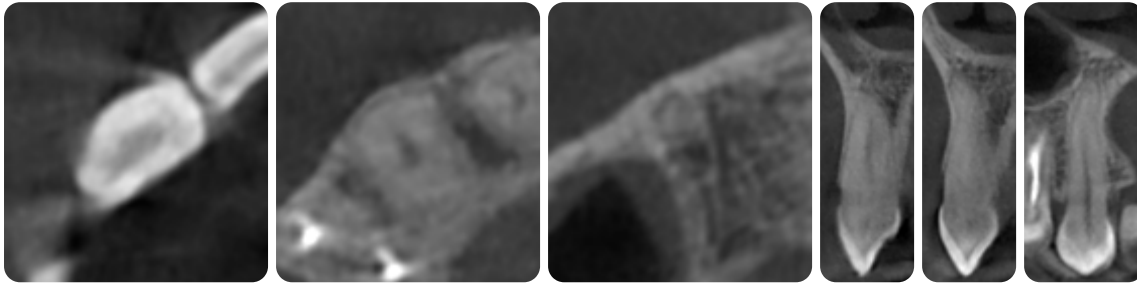
● Tooth 14

Tooth, Filling, 2 roots, 2 canals, Endodontically treated tooth
(Adequate obturation, Adequate density)



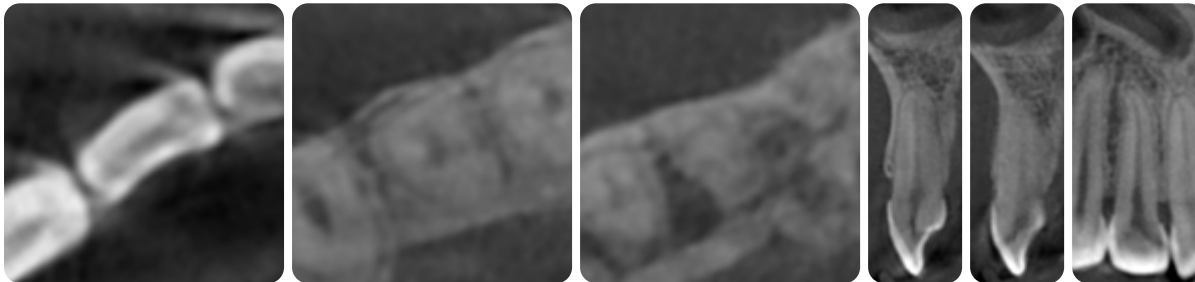
○ Tooth 13

Tooth, 1 root, 1 canal



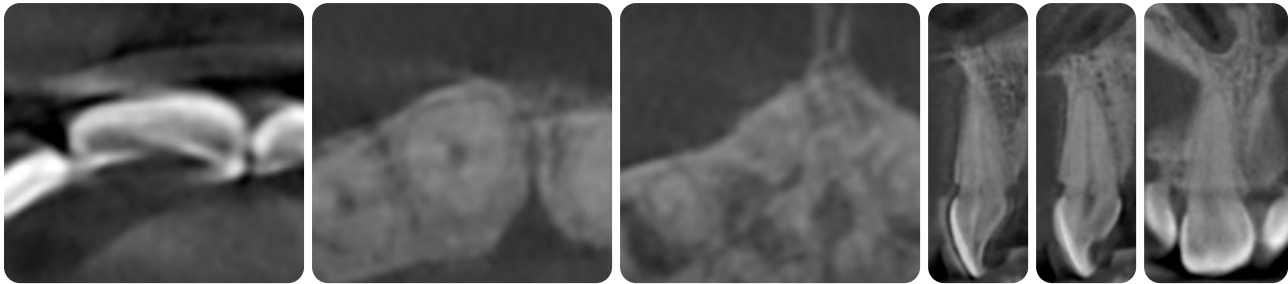
○ Tooth 12

Tooth, 1 root, 1 canal



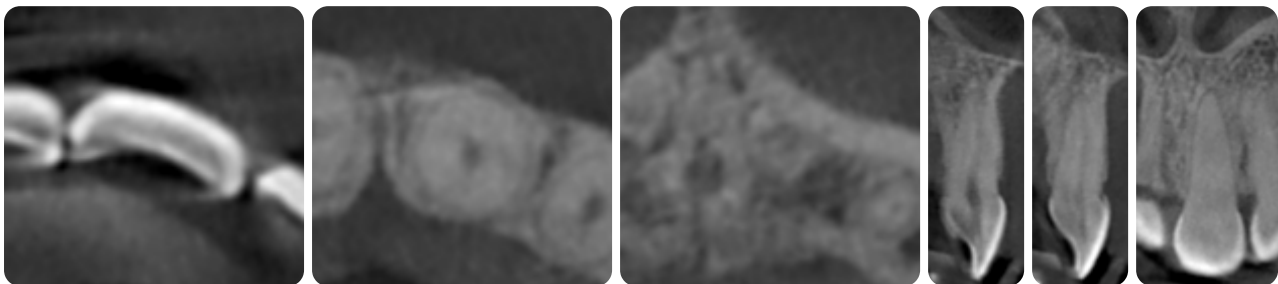
○ Tooth 11

Tooth, 1 root, 1 canal, Pulp stone



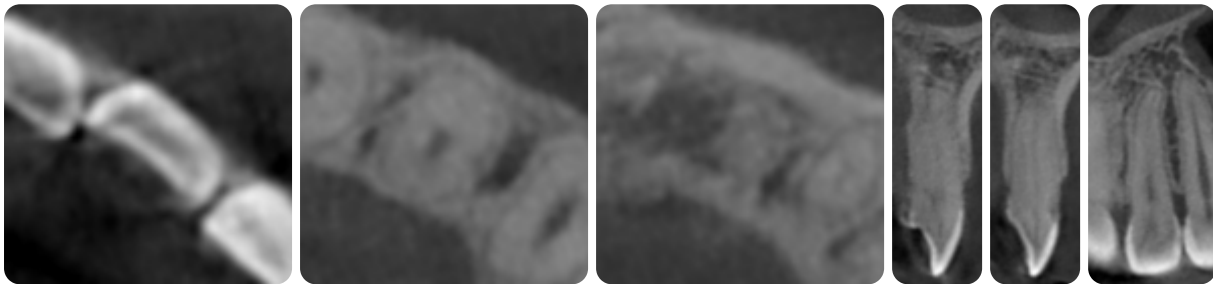
○ Tooth 21

Tooth, 1 root, 1 canal



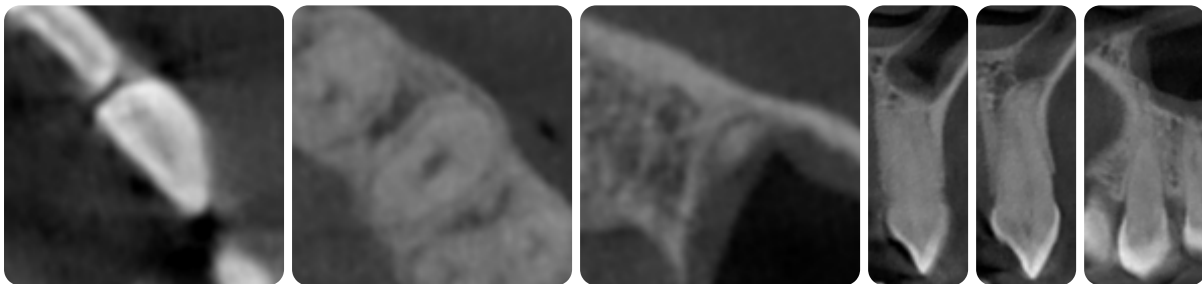
○ Tooth 22

Tooth, 1 root, 1 canal, Pulp stone



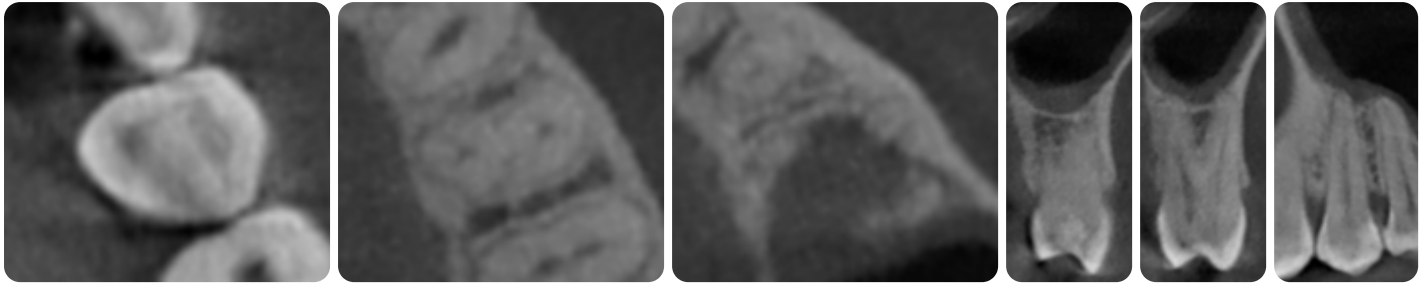
○ Tooth 23

Tooth, 1 root, 1 canal



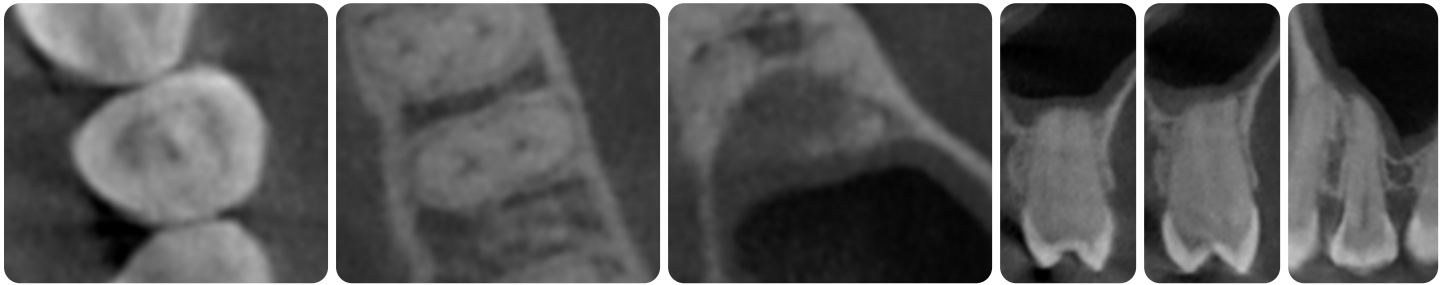
● Tooth 24

Tooth, Filling, 2 roots, 2 canals



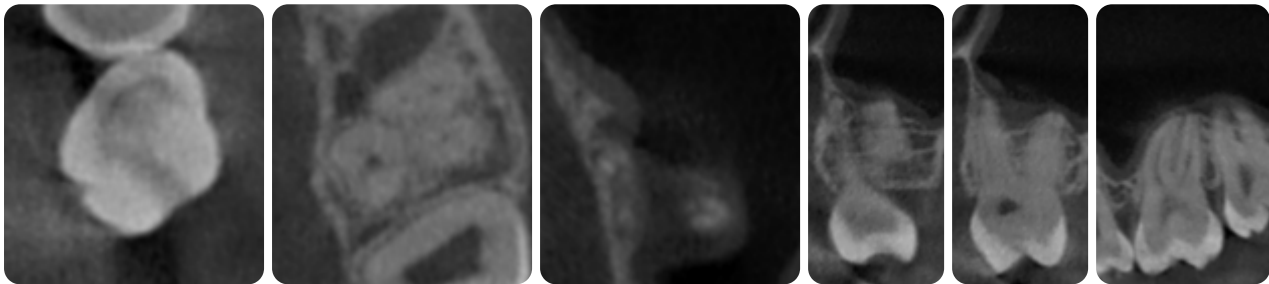
● Tooth 25

Tooth, 1 root, 2 canals, Caries signs (Dentin, Mesial)



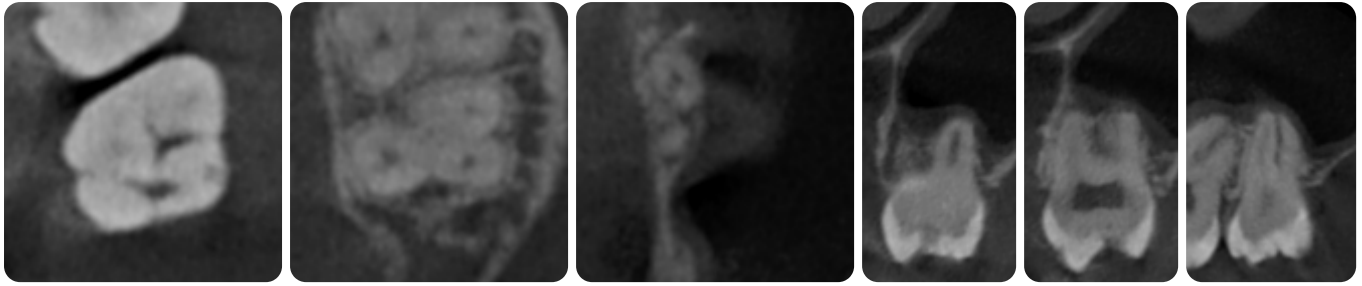
● Tooth 26

Tooth, Filling, 3 roots, 4 canals, Pulp stone



● Tooth 27

Tooth, 3 roots, 4 canals, Caries signs (Dentin, Occlusal)

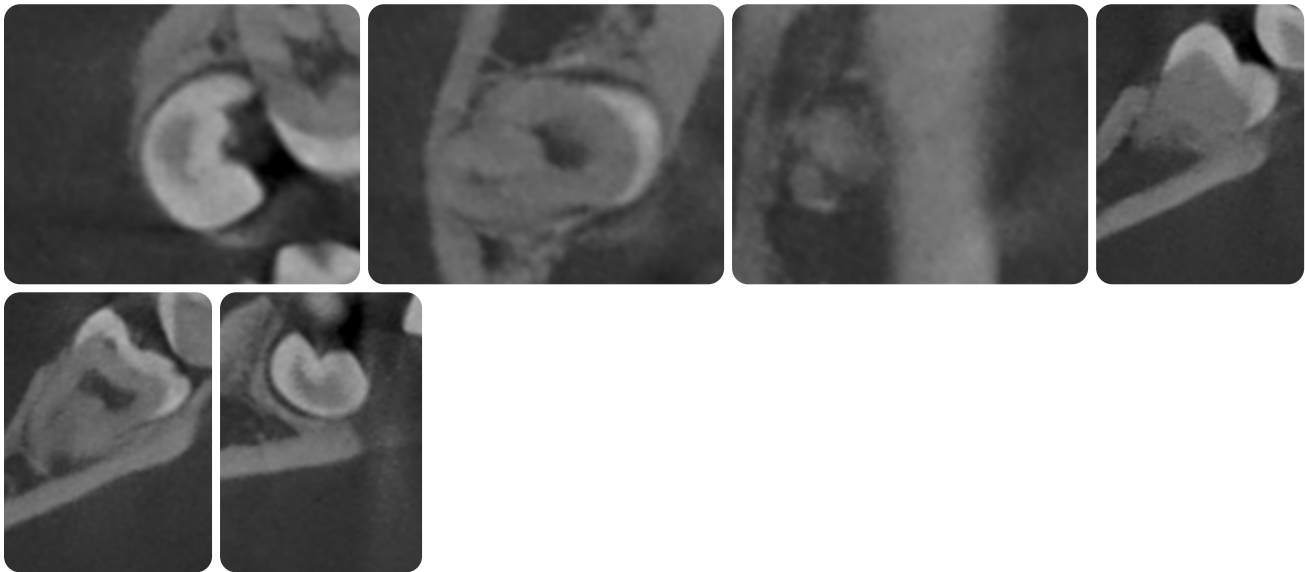


Tooth 28

Missing

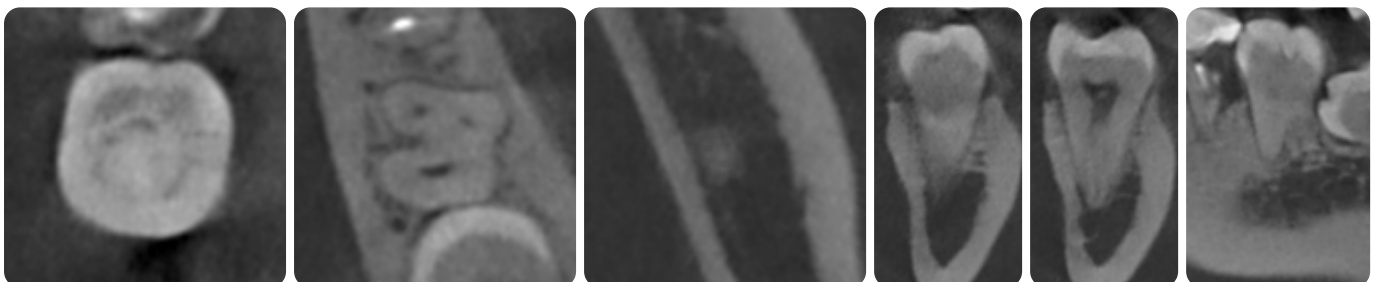
● Tooth 38

Tooth, Impaction, 2 roots, 3 canals



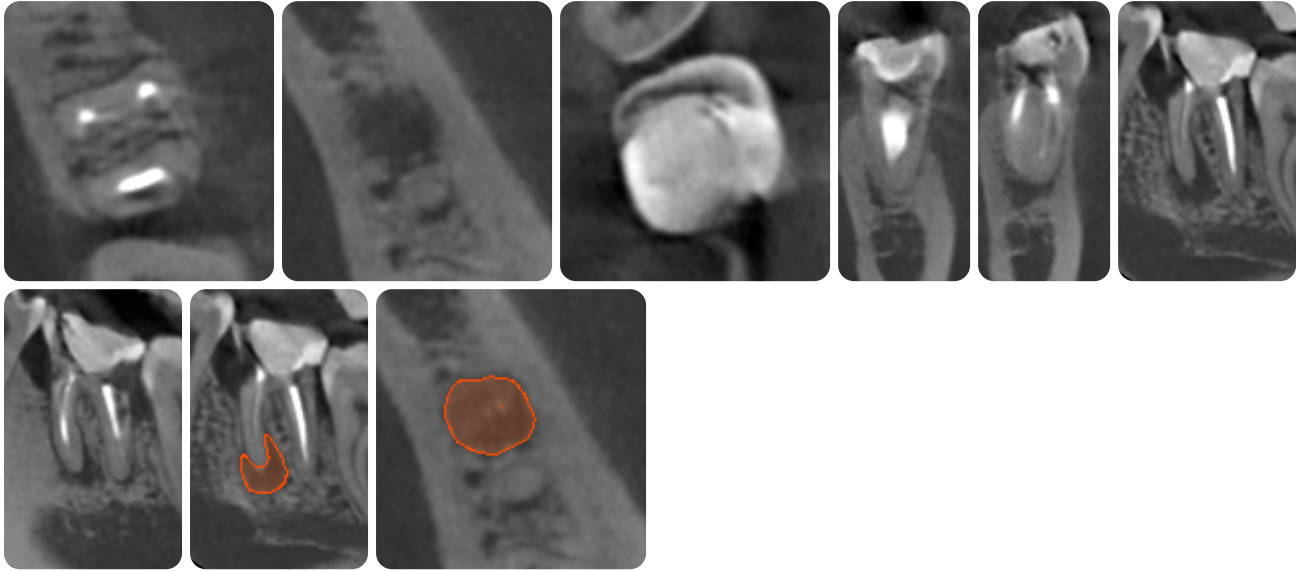
○ Tooth 37

Tooth, 1 root, 3 canals



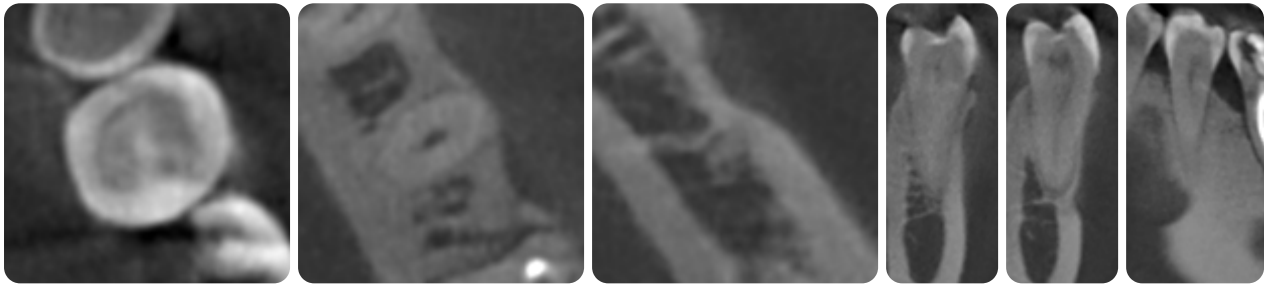
● Tooth 36

Tooth, Filling, 2 roots, 3 canals, Caries signs (Dentin, Root, Mesial, Distal), Endodontically treated tooth (Short filling, Adequate density), Periapical radiopacity, PDL space widening along the root, Periodontal bone loss (Moderate, Horizontal), Periapical radiolucency



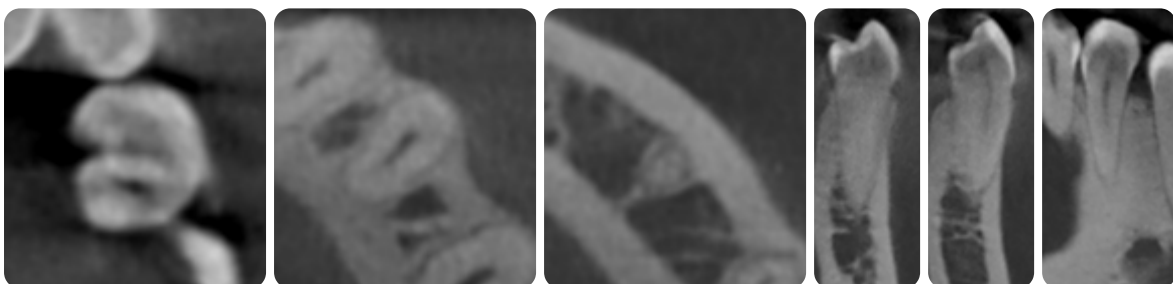
○ Tooth 35

Tooth, 1 root, 1 canal



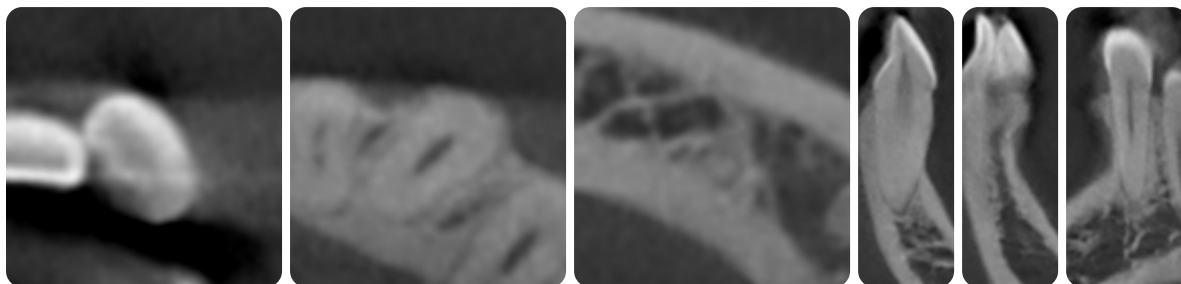
○ Tooth 34

Tooth, 1 root, 1 canal



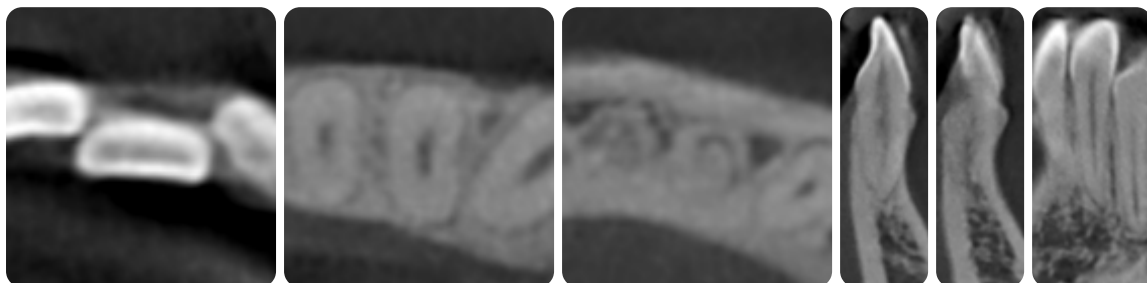
○ **Tooth 33**

Tooth, 1 root, 1 canal



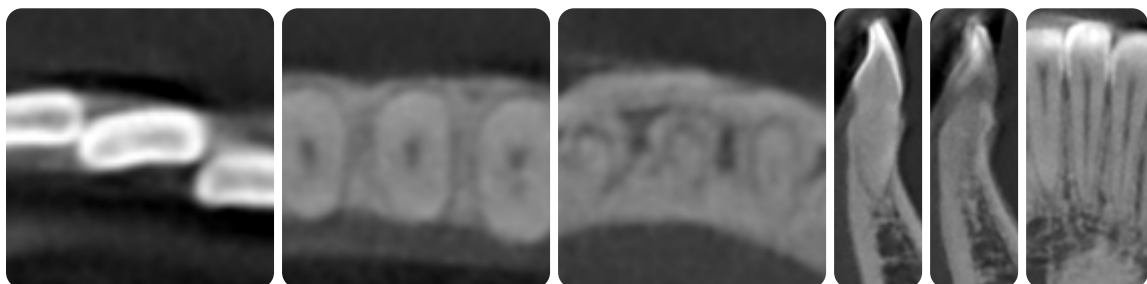
○ **Tooth 32**

Tooth, 1 root, 2 canals



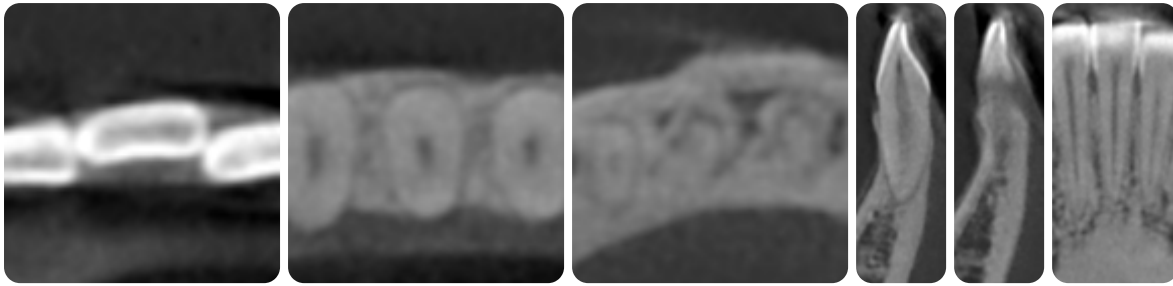
○ **Tooth 31**

Tooth, 1 root, 1 canal



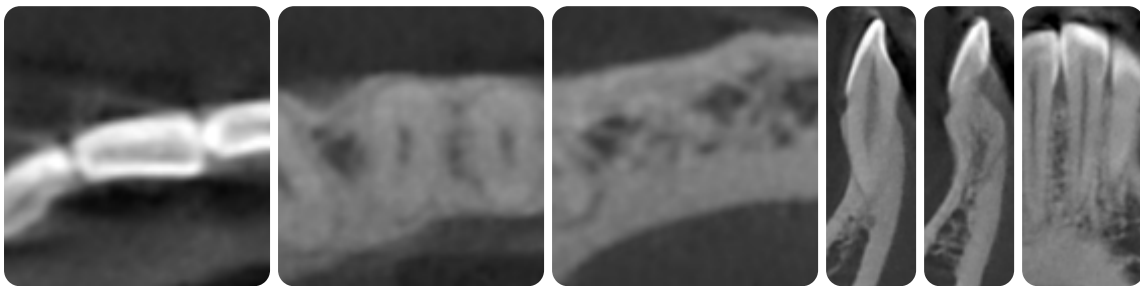
○ **Tooth 41**

Tooth, 1 root, 1 canal



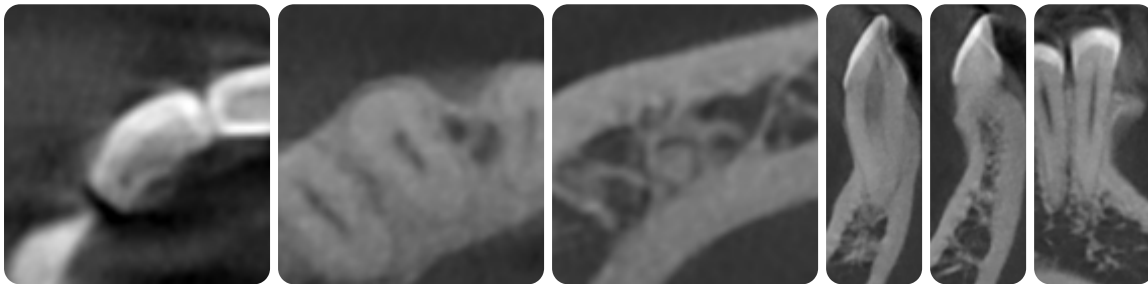
○ **Tooth 42**

Tooth, 1 root, 1 canal



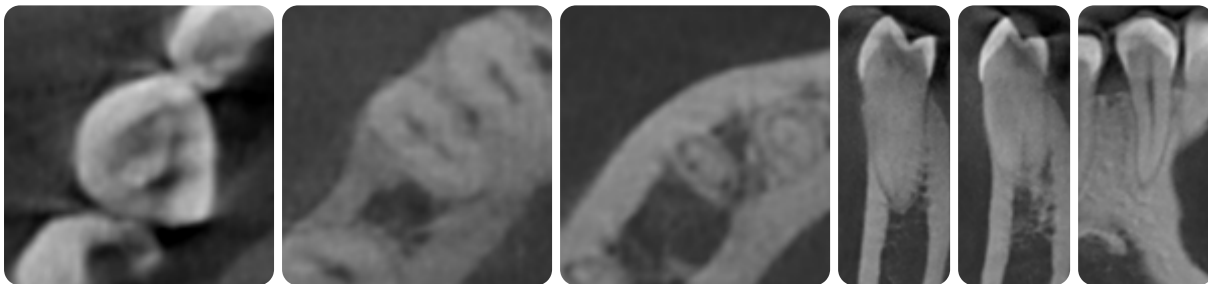
○ **Tooth 43**

Tooth, 1 root, 1 canal



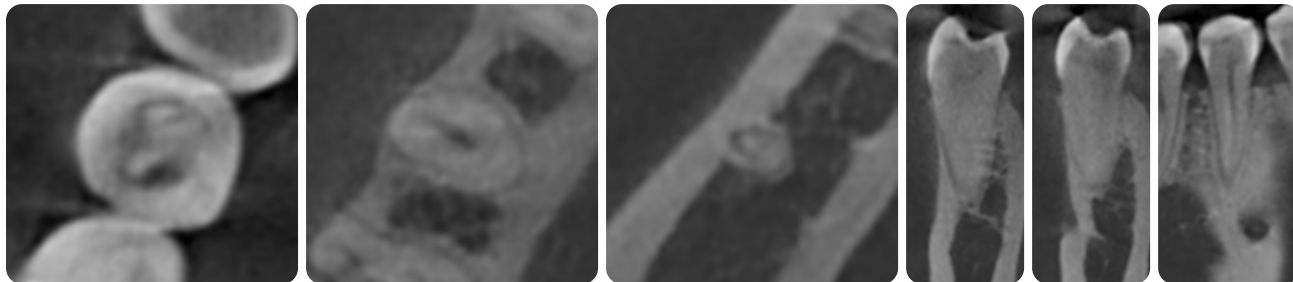
○ **Tooth 44**

Tooth, 1 root, 2 canals



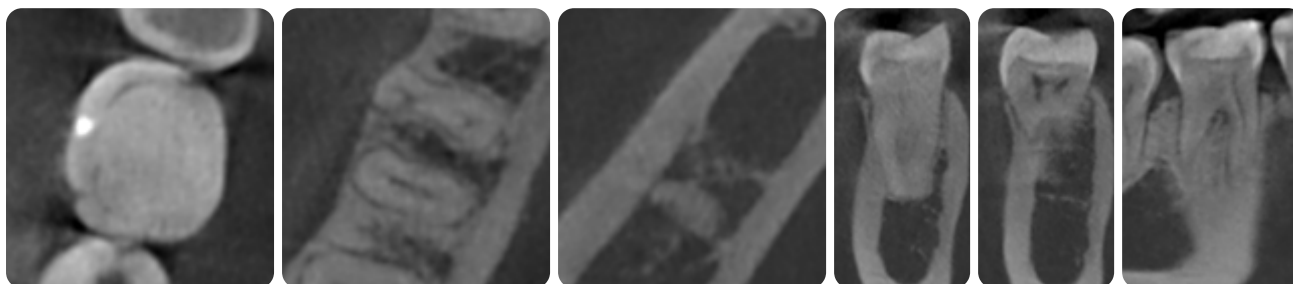
○ Tooth 45

Tooth, 1 root, 1 canal



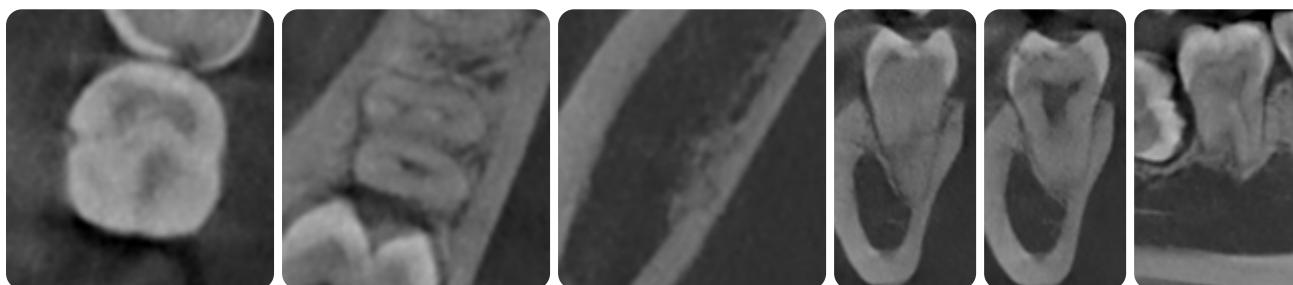
● Tooth 46

Tooth, **Filling**, 2 roots, 3 canals, **Caries signs (Dentin, Mesial, Distal)**



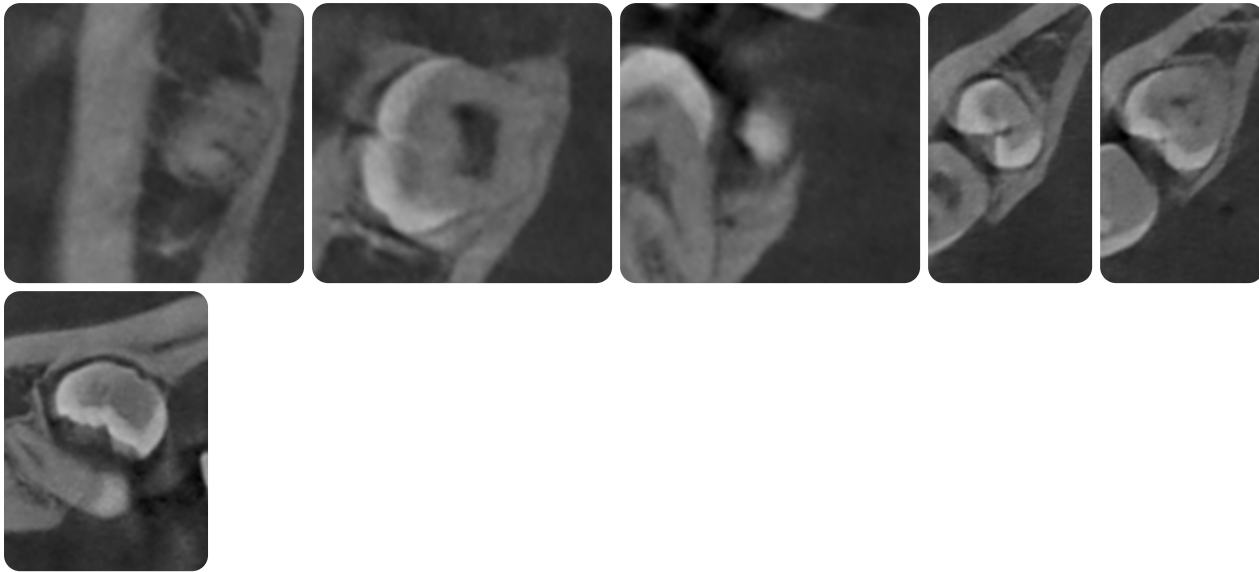
● Tooth 47

Tooth, **Filling**, 2 roots, 3 canals



● Tooth 48

Tooth, Impaction, 2 roots, 2 canals



Report signed: Jul 28, 2025, 9:52 AM



Dr. David Johnston
Dental Clinic
Schillerstraße 33
60313 Frankfurt am Main
+49 (0)69 61898293



Johnston David

Chief Dental Officer