

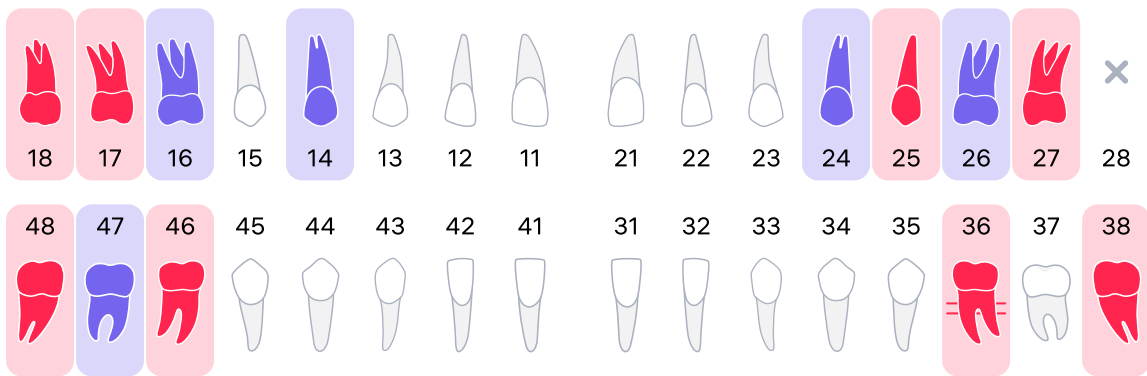
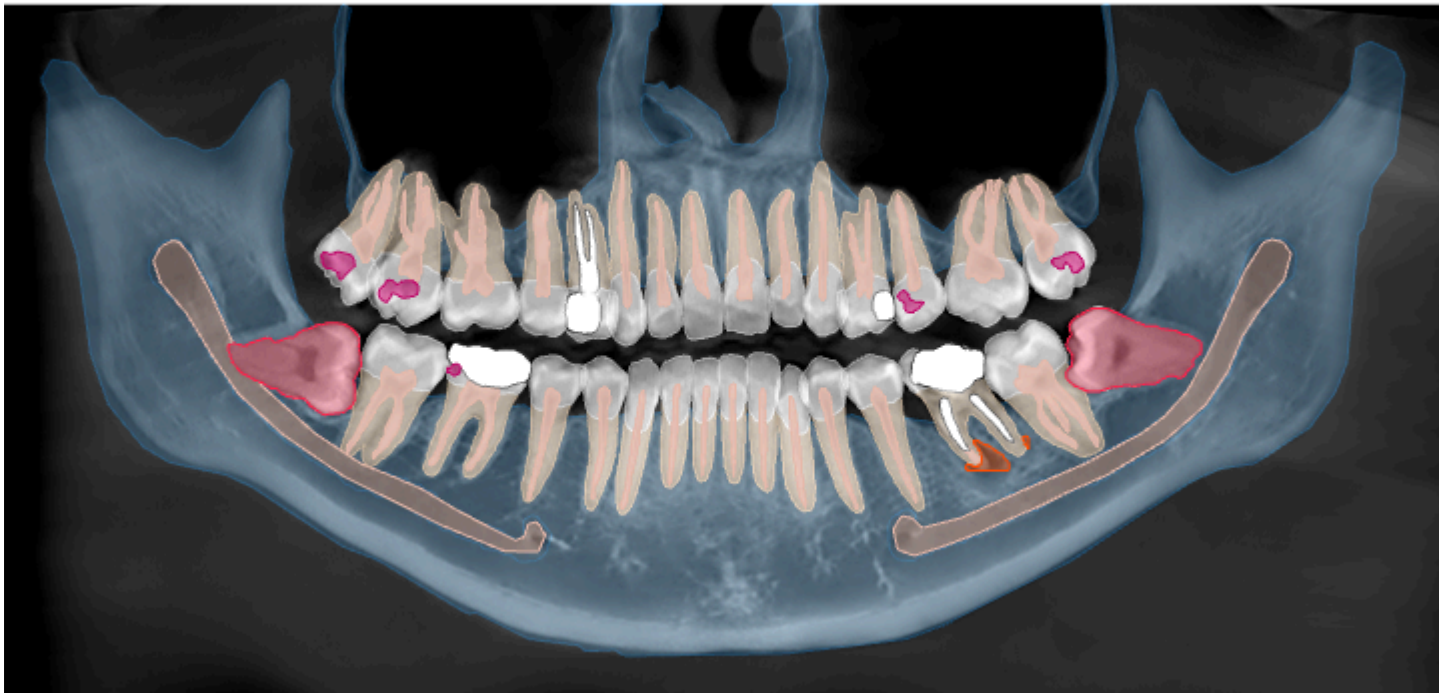


### Dental Clinic

ON M5S 2B3, Canada, Toronto  
6698 Bay Street  
647-560-7850  
info@dentalclinic.ca  
https://www.dentalclinic.ca

# CBCT AI Report

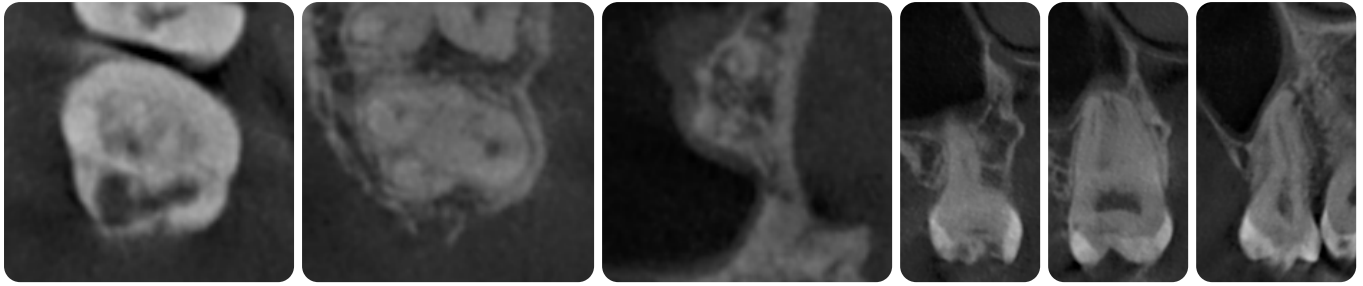
Veronica Kennard DoB: November 1, 1971, 53 y.o. Study Date: Jan 27, 2025, 11:19 AM



● Unhealthy ● Treated ○ Healthy ✗ Missing

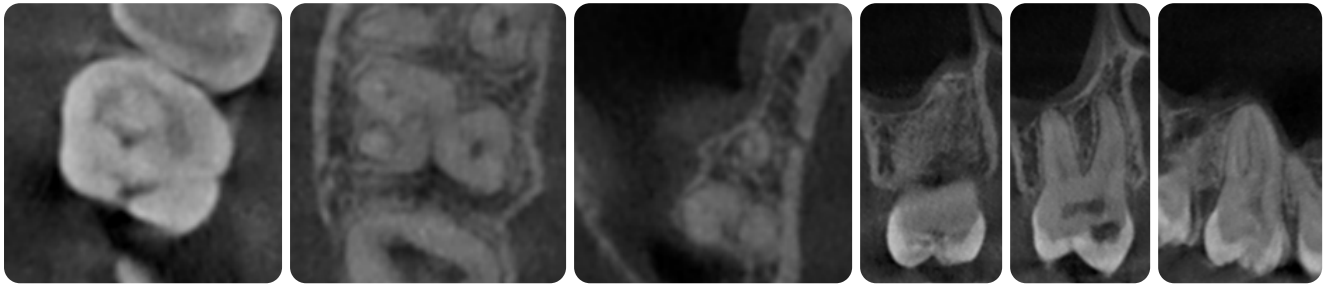
### ● Tooth 18

Tooth, 3 roots, 4 canals, Caries signs (Dentin, Buccal, Occlusal)



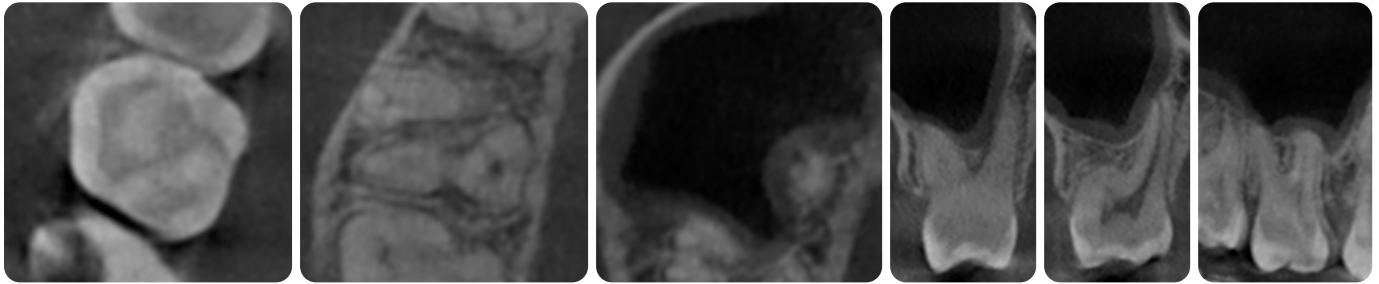
### ● Tooth 17

Tooth, 3 roots, 4 canals, Caries signs (Dentin, Occlusal)



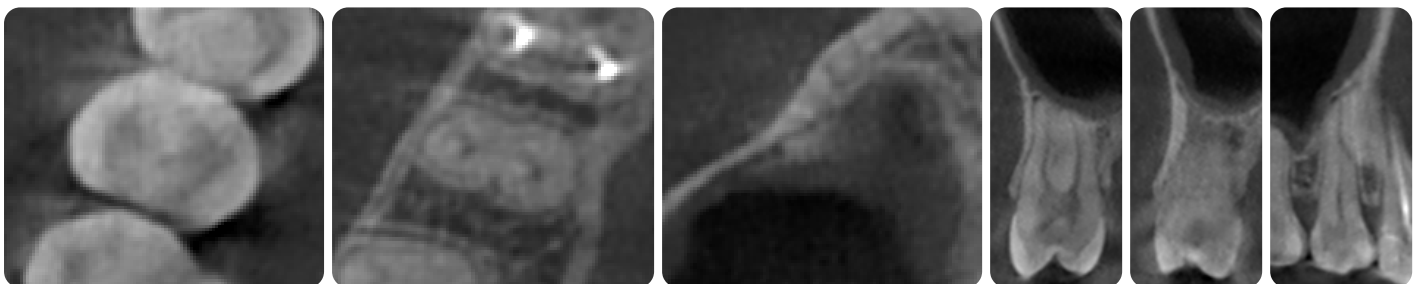
### ● Tooth 16

Tooth, Filling, 3 roots, 4 canals, Pulp stone



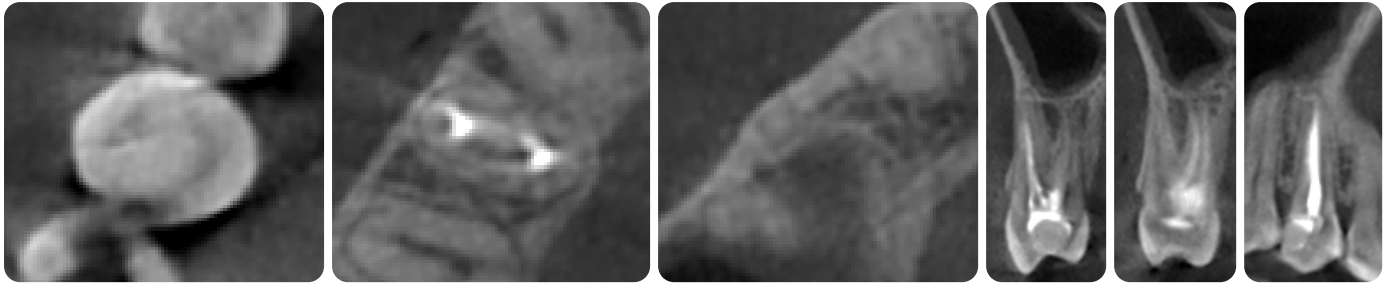
### ○ Tooth 15

Tooth, 1 root, 2 canals



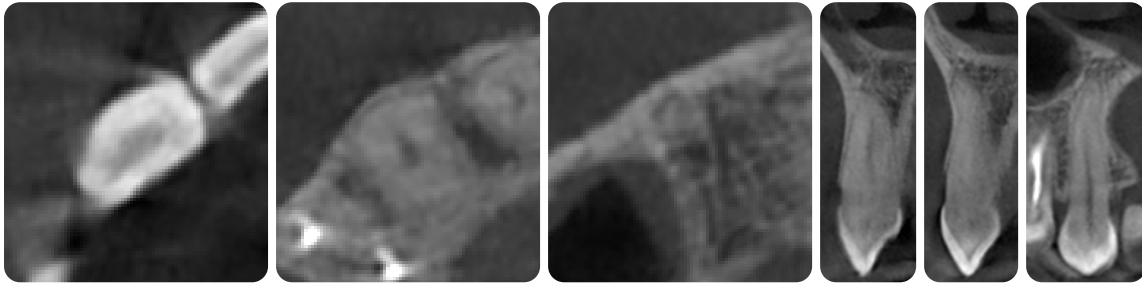
## ● Tooth 14

Tooth, Filling, 2 roots, 2 canals, Endodontically treated tooth  
(Adequate obturation, Adequate density)



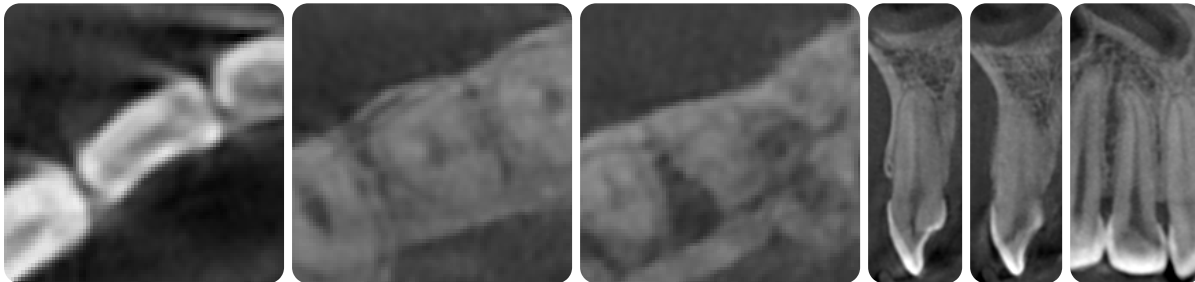
## ○ Tooth 13

Tooth, 1 root, 1 canal



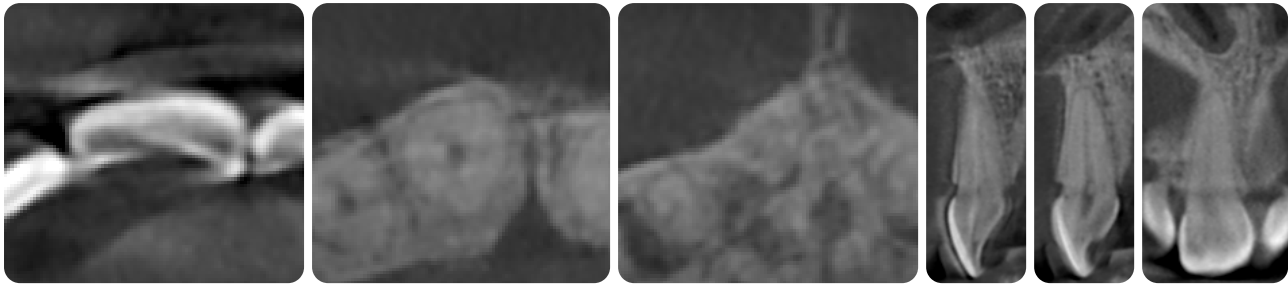
## ○ Tooth 12

Tooth, 1 root, 1 canal



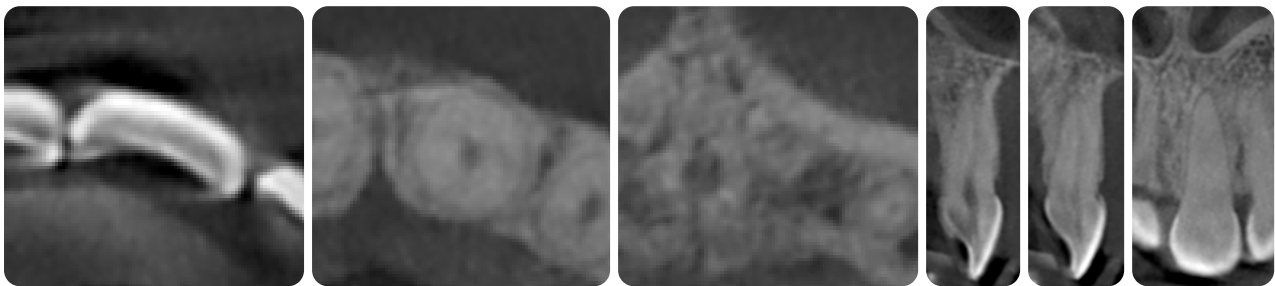
## ○ Tooth 11

Tooth, 1 root, 1 canal, Pulp stone



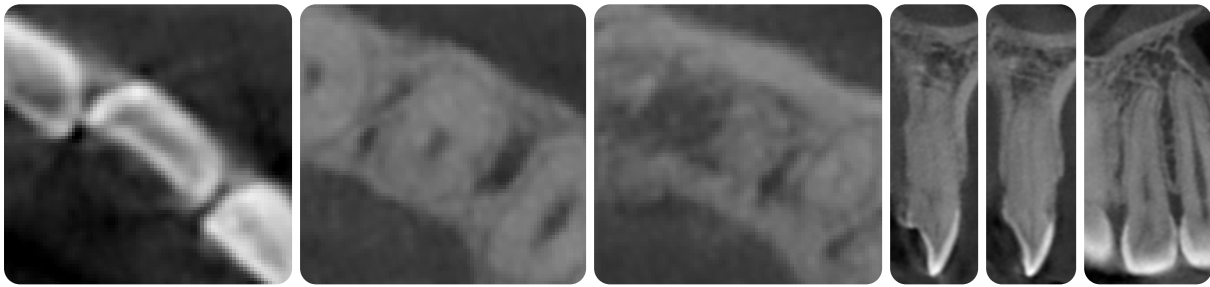
## ○ Tooth 21

Tooth, 1 root, 1 canal



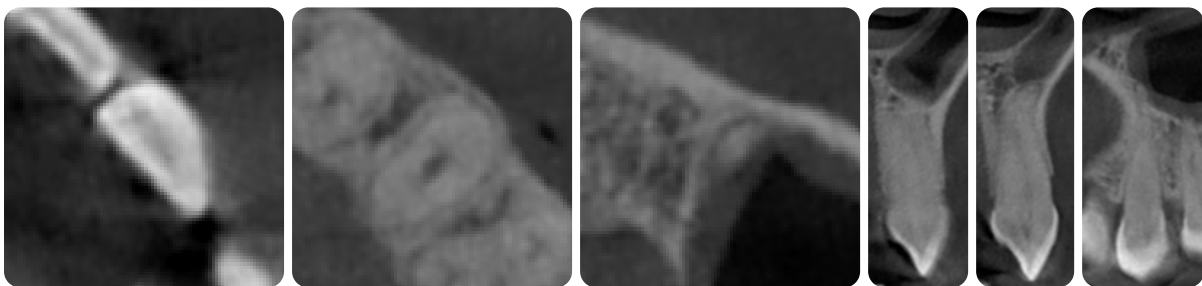
## ○ Tooth 22

Tooth, 1 root, 1 canal, Pulp stone



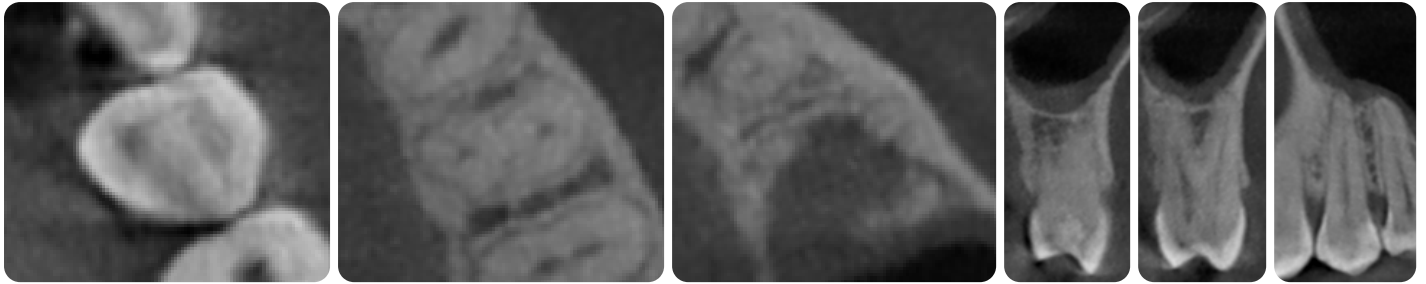
## ○ Tooth 23

Tooth, 1 root, 1 canal



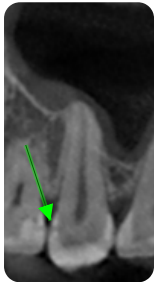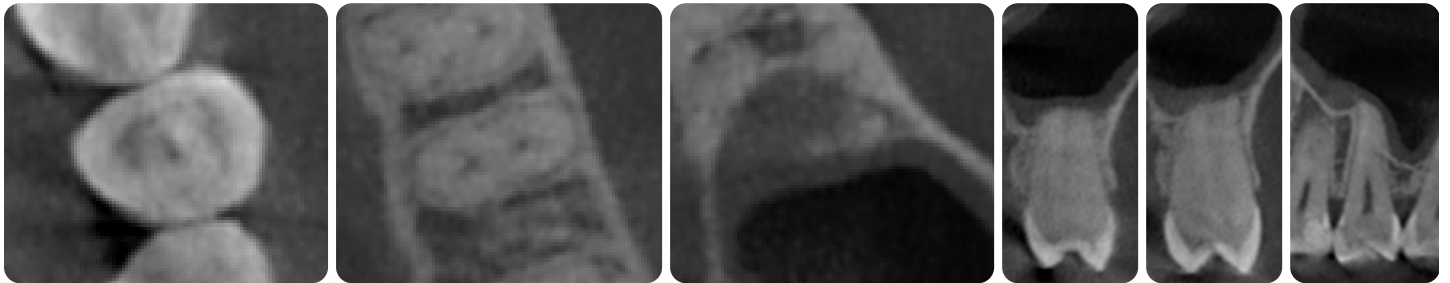## ● Tooth 24

Tooth, **Filling**, 2 roots, 2 canals



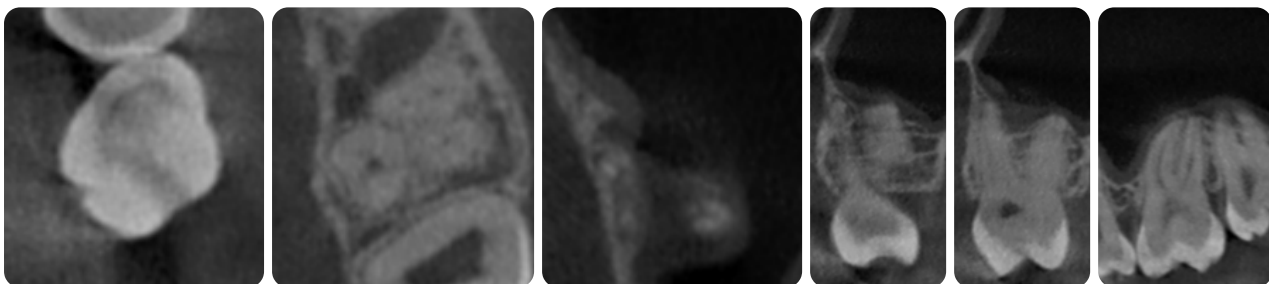
## ● Tooth 25

Tooth, 1 root, 2 canals, **Caries signs (Dentin, Mesial)**



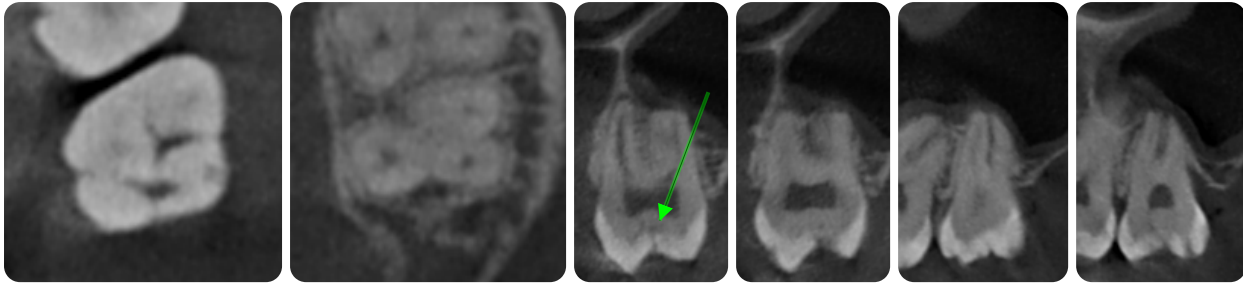
## ● Tooth 26

Tooth, **Filling**, 3 roots, 4 canals, Pulp stone



## ● Tooth 27

Tooth, 3 roots, 4 canals, Caries signs (Dentin, Occlusal)

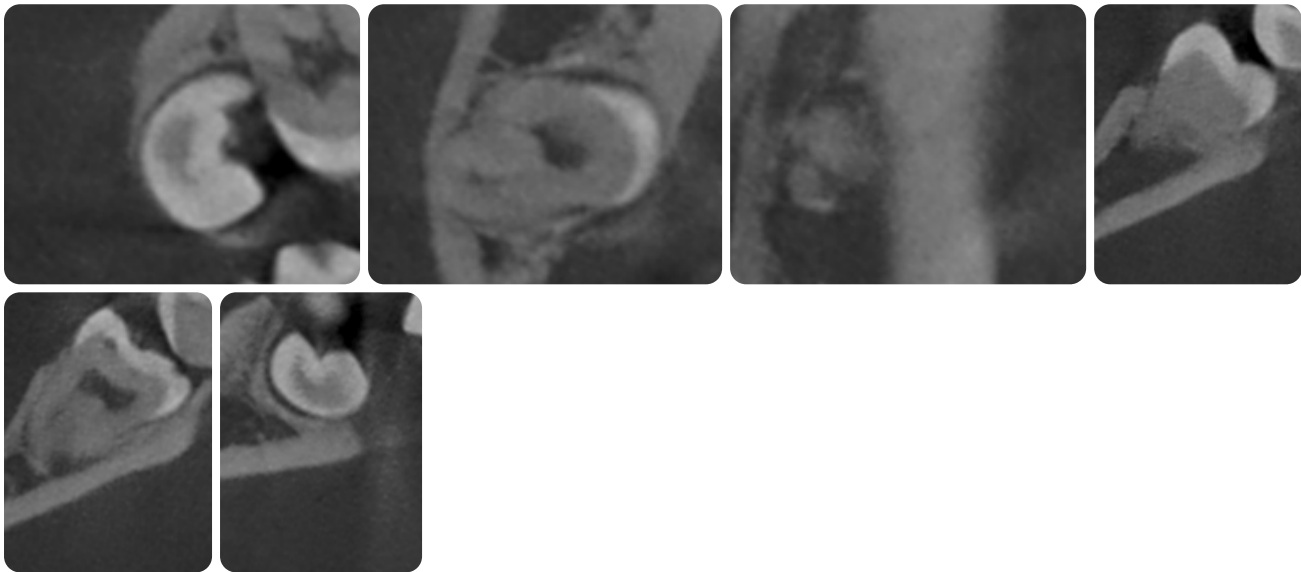


## ● Tooth 28

Missing

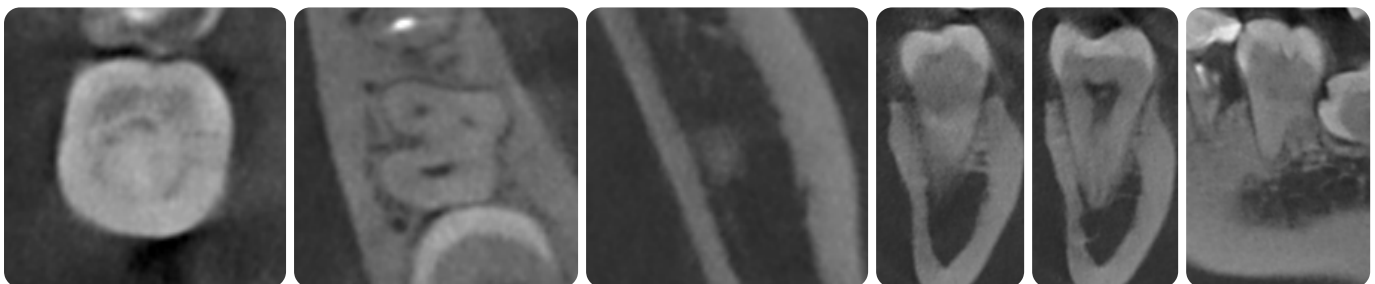
## ● Tooth 38

Tooth, Impaction, 2 roots, 3 canals



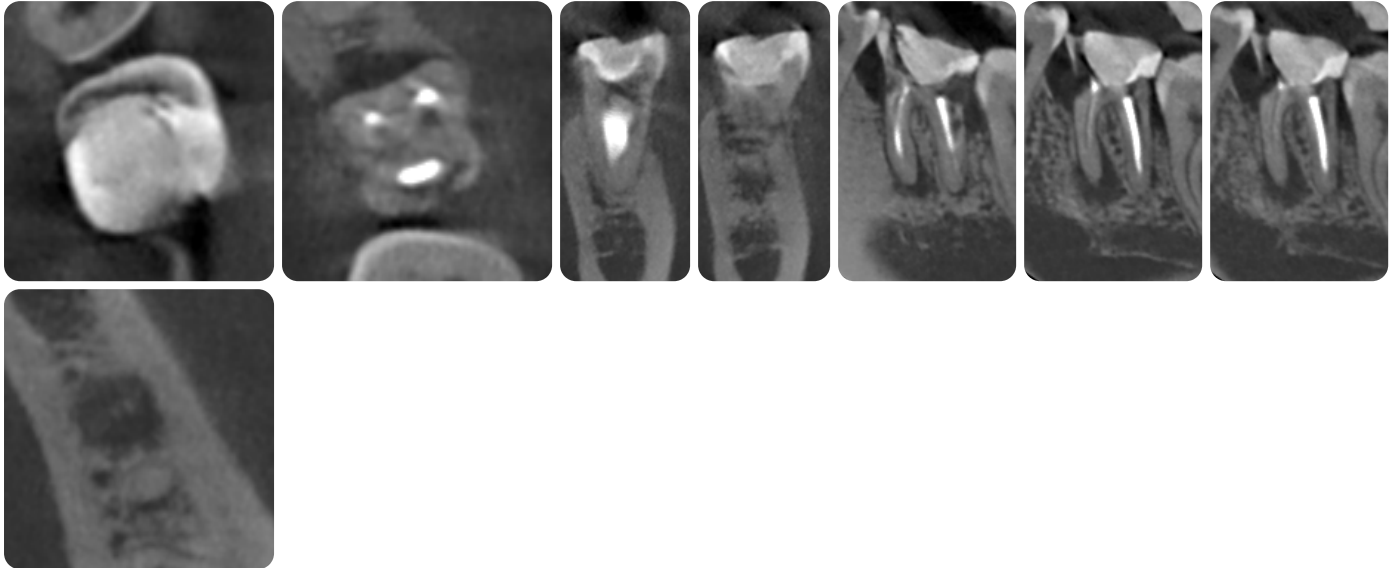
## ○ Tooth 37

Tooth, 1 root, 3 canals



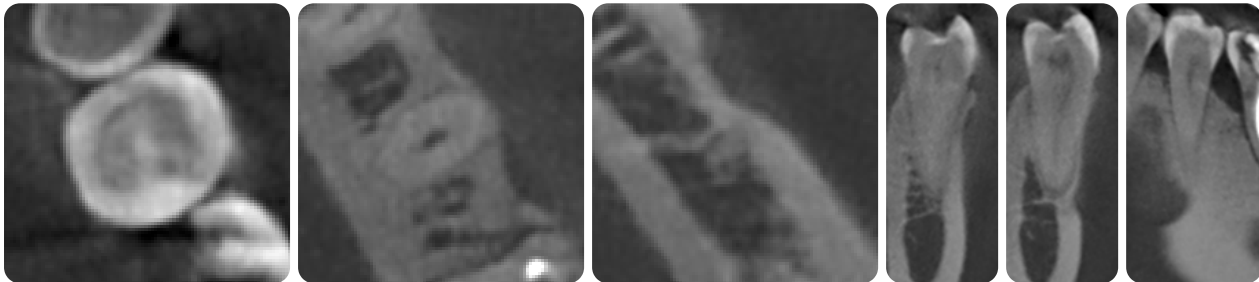
## ● Tooth 36

Tooth, Filling, 2 roots, 3 canals, Caries signs (Dentin, Root, Mesial, Distal), Endodontically treated tooth (Short filling, Adequate density), Periapical radiopacity, PDL space widening along the root, Periodontal bone loss (Moderate, Horizontal), Periapical radiolucency



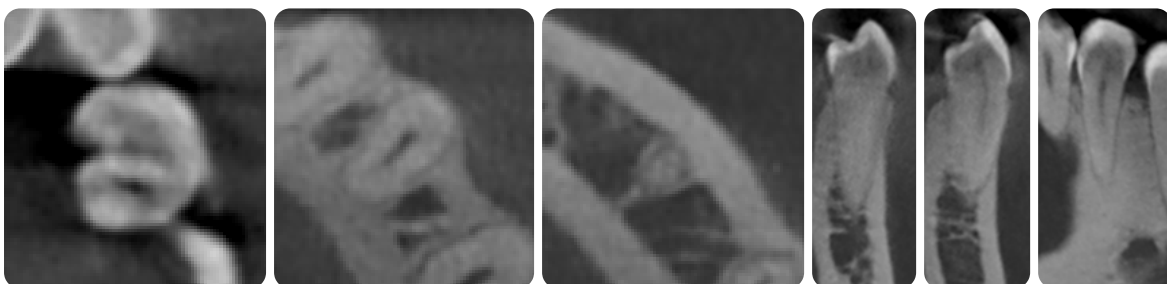## ○ Tooth 35

Tooth, 1 root, 1 canal



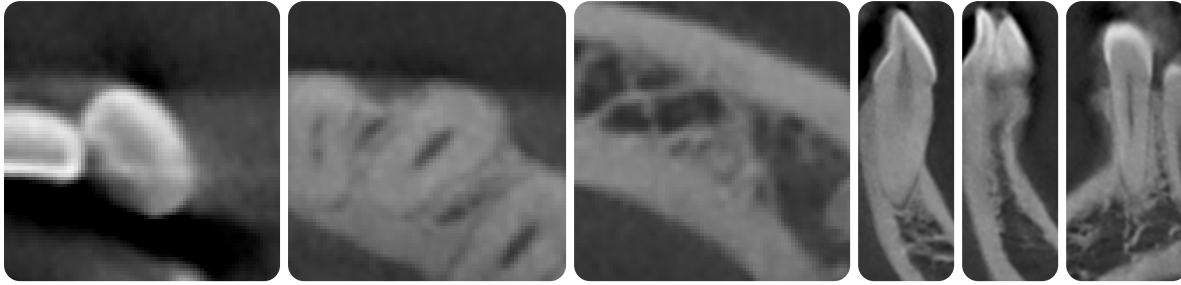
## ○ Tooth 34

Tooth, 1 root, 1 canal



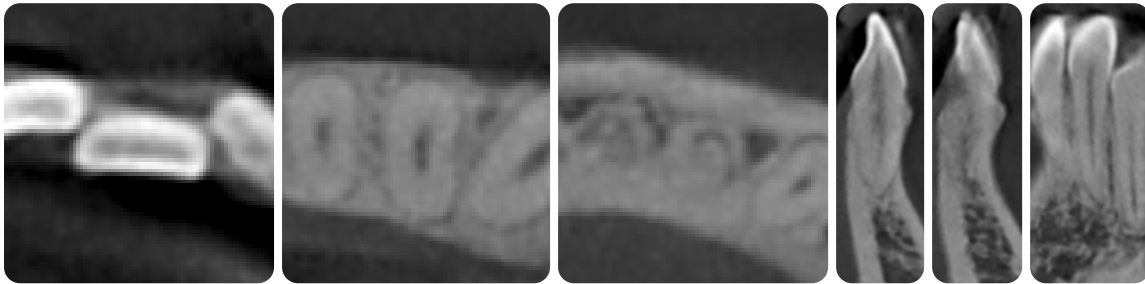
### ○ **Tooth 33**

Tooth, 1 root, 1 canal



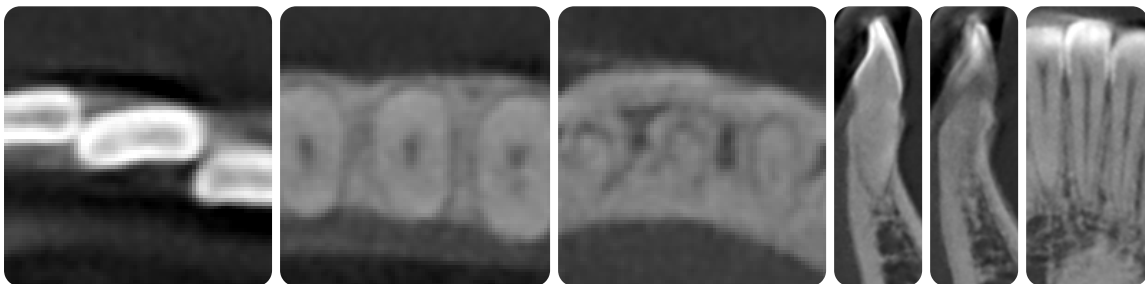
### ○ **Tooth 32**

Tooth, 1 root, 2 canals



### ○ **Tooth 31**

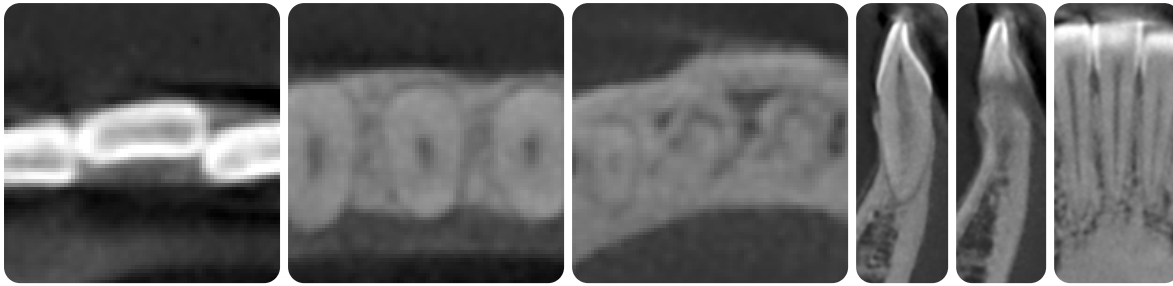
Tooth, 1 root, 1 canal





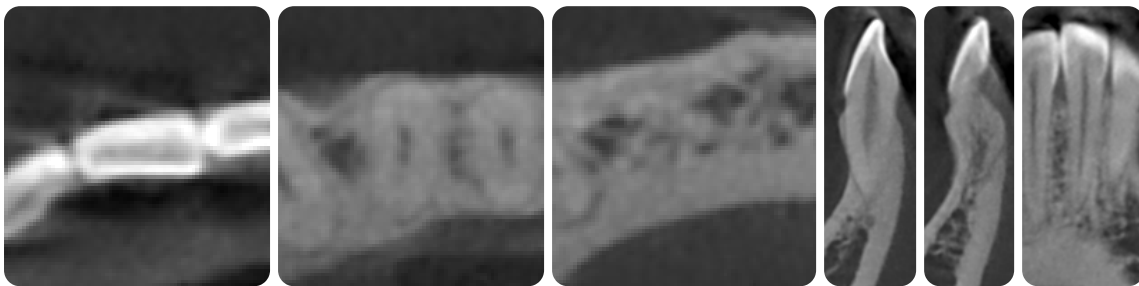
### ○ **Tooth 41**

Tooth, 1 root, 1 canal



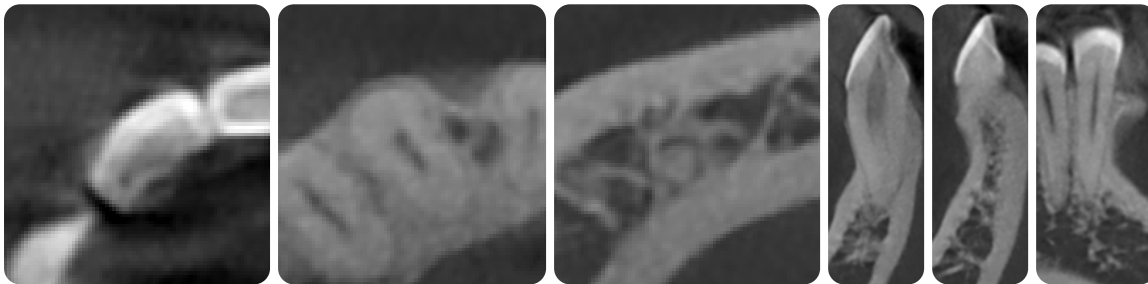
### ○ **Tooth 42**

Tooth, 1 root, 1 canal



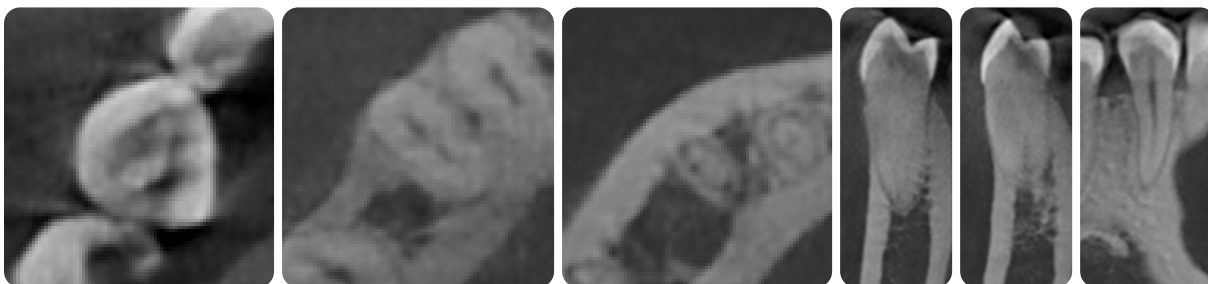
### ○ **Tooth 43**

Tooth, 1 root, 1 canal



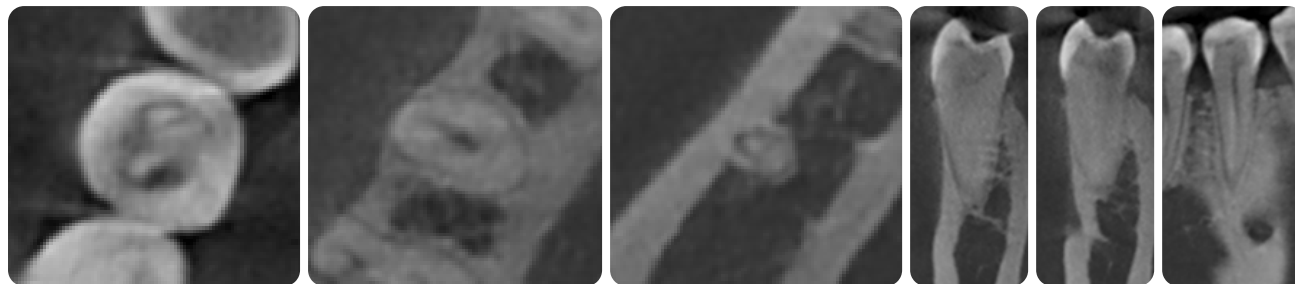
### ○ **Tooth 44**

Tooth, 1 root, 2 canals



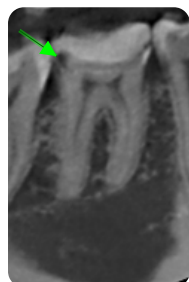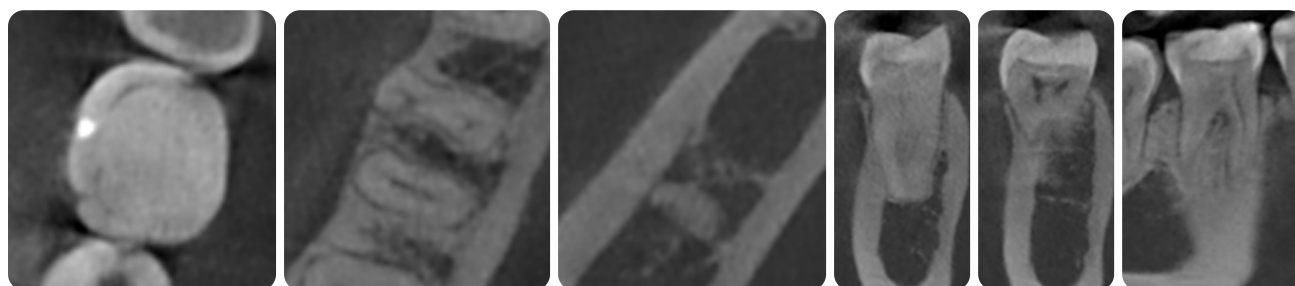
## ○ Tooth 45

Tooth, 1 root, 1 canal



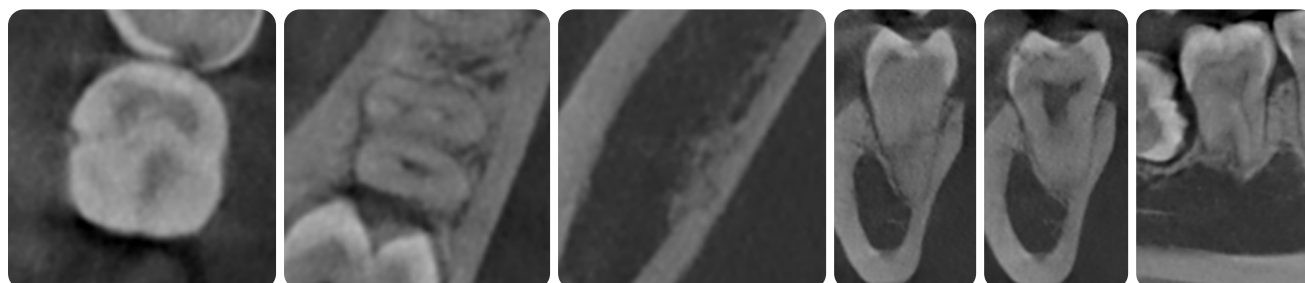
## ● Tooth 46

Tooth, Filling, 2 roots, 3 canals, Caries signs (Dentin, Distal)



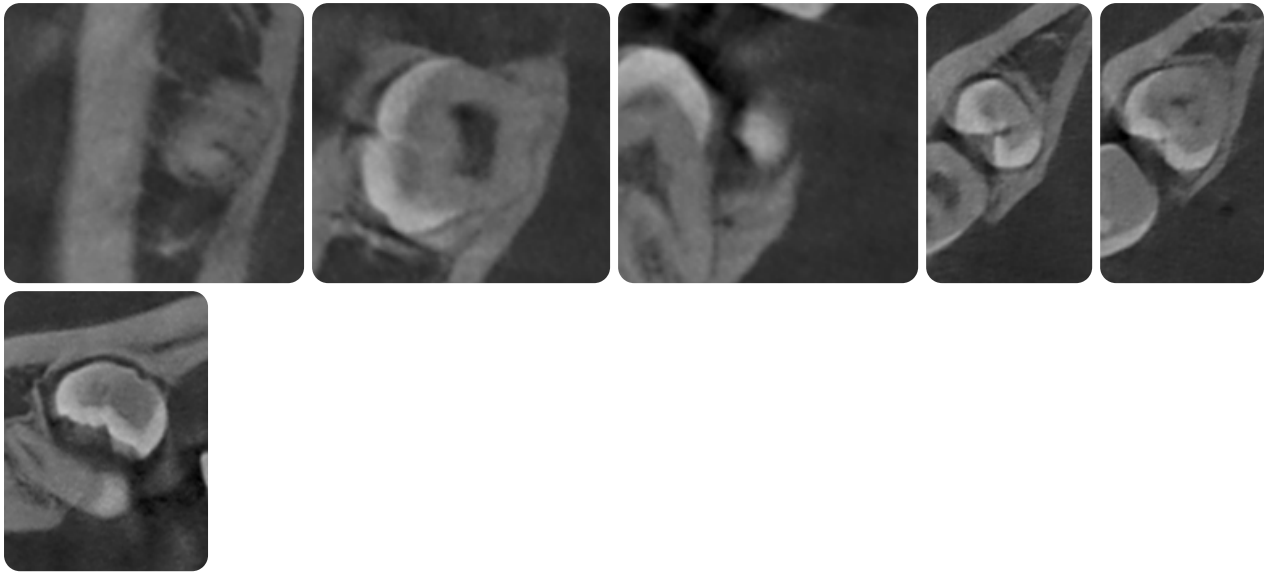
## ● Tooth 47

Tooth, Filling, 2 roots, 3 canals



# ● Tooth 48

Tooth, Impaction, 2 roots, 2 canals



**Paul Fisher**

Chief Dental  
Officer



Dr. Paul Fisher  
Dentist

6698 Bay Street | Toronto,  
Canada ON M5S 2B3  
547-560-7850

E: info@dentalclinic.ca | W: https://www.dentalclinic.ca



Report signed:

Mar 4, 2025, 4:09 PM