**Dental Clinic**

ON M5S 2B3, Canada, Central Canada, Toronto  
6698 Bay Street  
neodentalclinic33@gmail.com

# CBCT AI Report


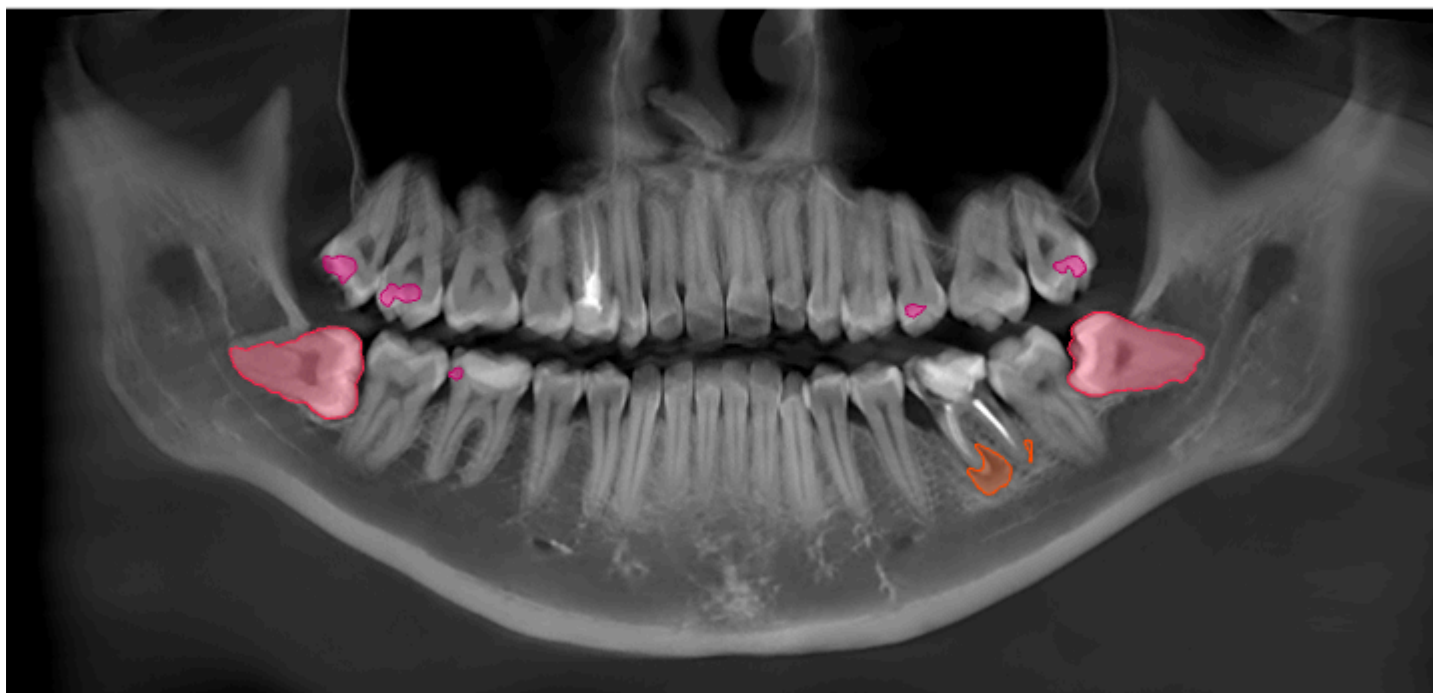
Patient: Charlotte Anderson  
DOB: 54 years  
Address: not specified  
Prescribing doctor: not specified

Study Date:	Sep 18, 2024, 10:38 AM	Type of Scan:	not specified
FOV:	not specified	Scan Source:	not specified
CBCT Model:	ORTHOPHOS S	Indication for Scan / Referral Notes:	not specified

Limitations or Technical Factors During Image Acquisition: not specified

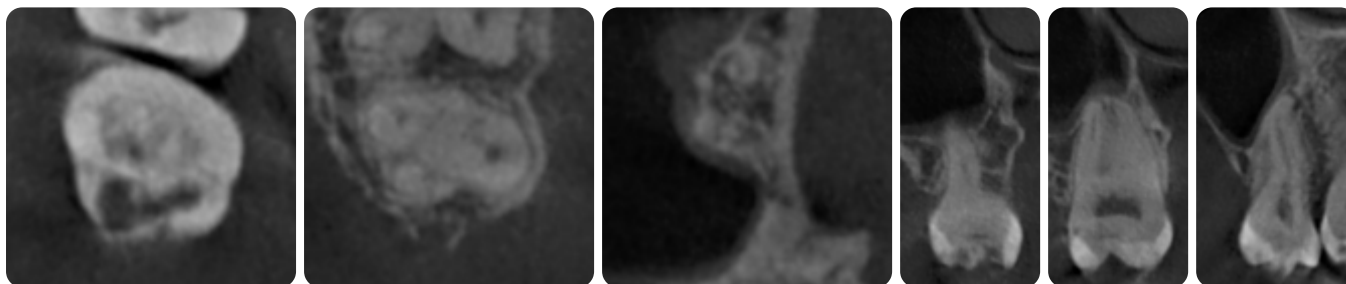
**OBSERVATIONS:** not specified  
DENTITION: not specified  
AREA OF INTEREST: not specified  
SINUSES: not specified  
AIRWAY: not specified  
OSSEOUS: not specified  
ADDITIONAL: not specified

**IMPRESSIONS:** not specified



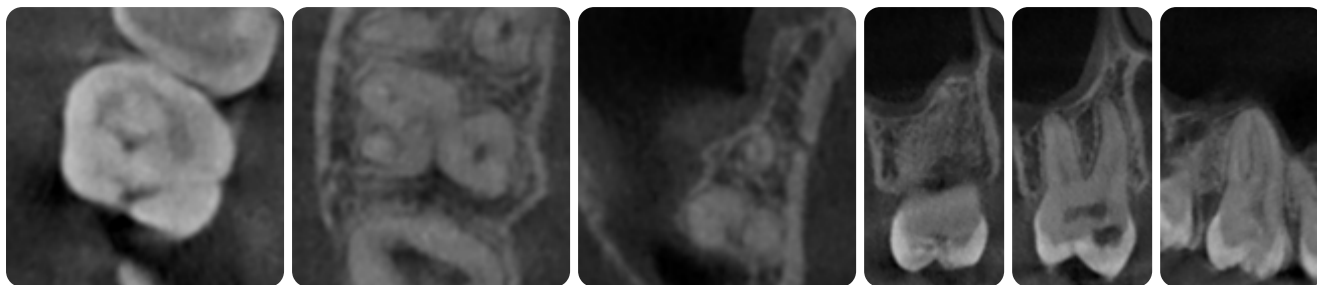
## ● Tooth 18

Tooth, 3 roots, 4 canals, Caries signs (Dentin, Buccal, Occlusal)



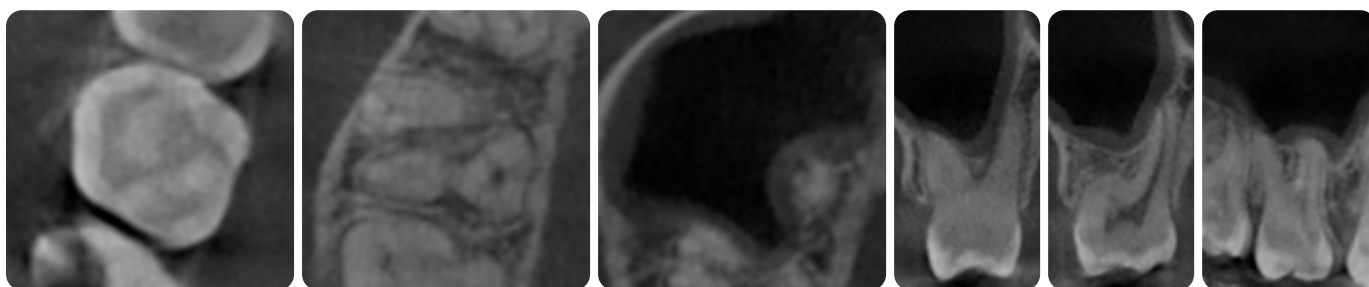
## ● Tooth 17

Tooth, 3 roots, 4 canals, Caries signs (Dentin, Occlusal)



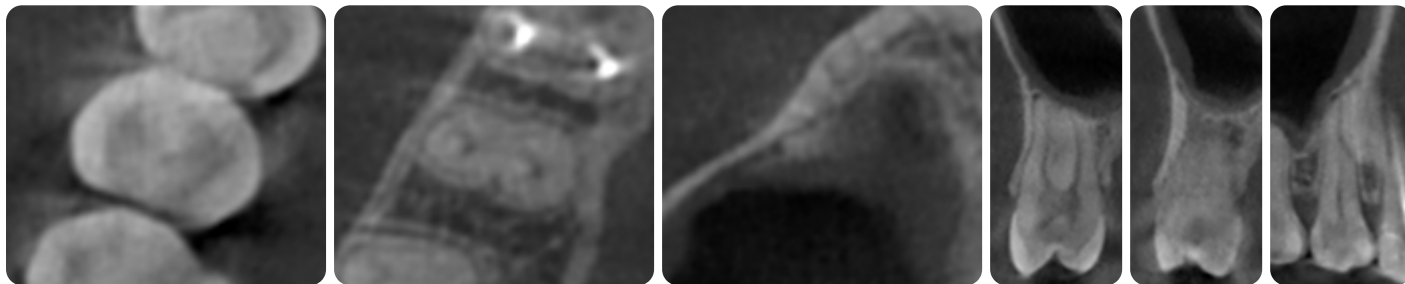
## ● Tooth 16

Tooth, Filling, 3 roots, 4 canals, Pulp stone



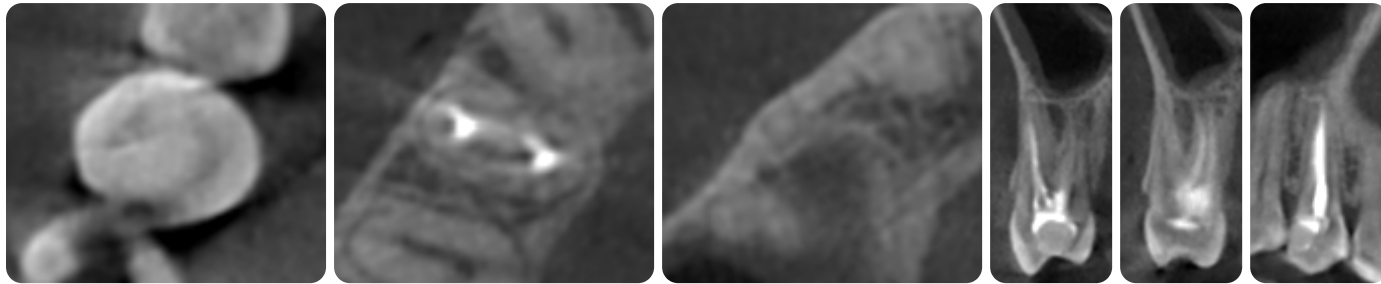
## ○ Tooth 15

Tooth, 1 root, 2 canals



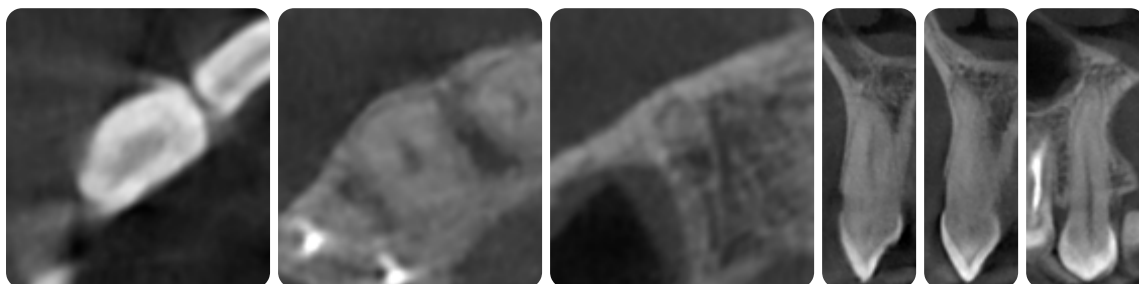
## ● Tooth 14

Tooth, Filling, 2 roots, 2 canals, Endodontically treated tooth  
(Adequate obturation, Adequate density)



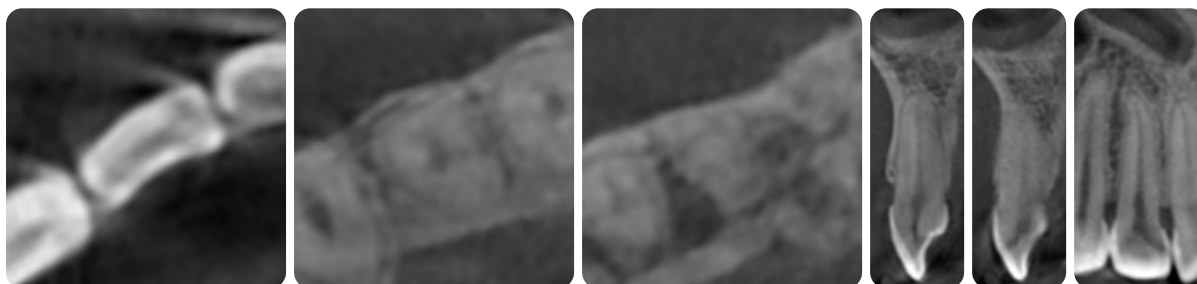
## ○ Tooth 13

Tooth, 1 root, 1 canal



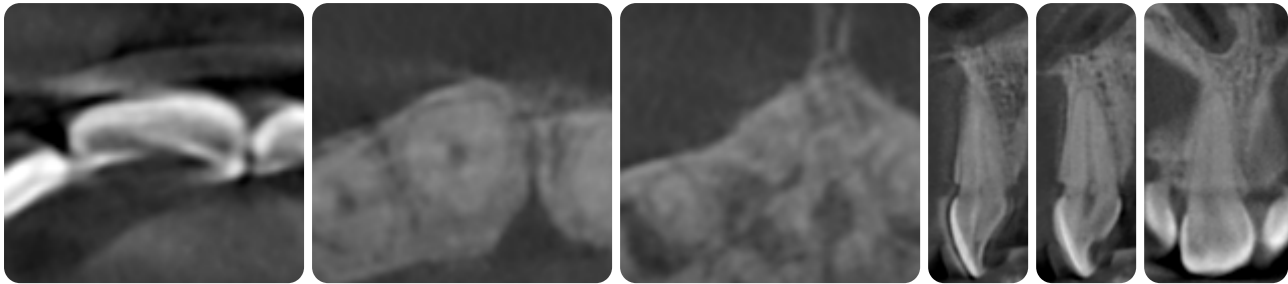
## ○ Tooth 12

Tooth, 1 root, 1 canal



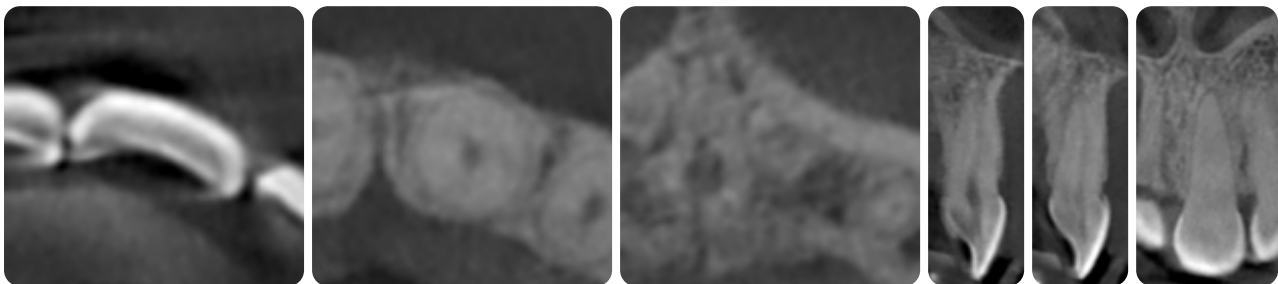
## ○ **Tooth 11**

Tooth, 1 root, 1 canal, Pulp stone



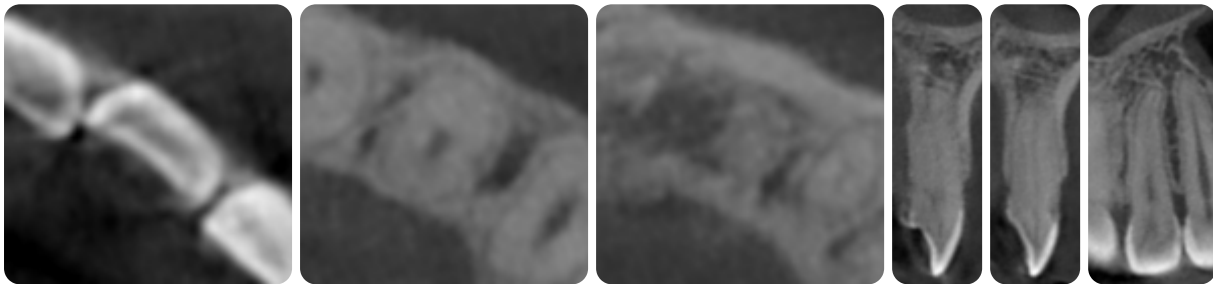
## ○ **Tooth 21**

Tooth, 1 root, 1 canal



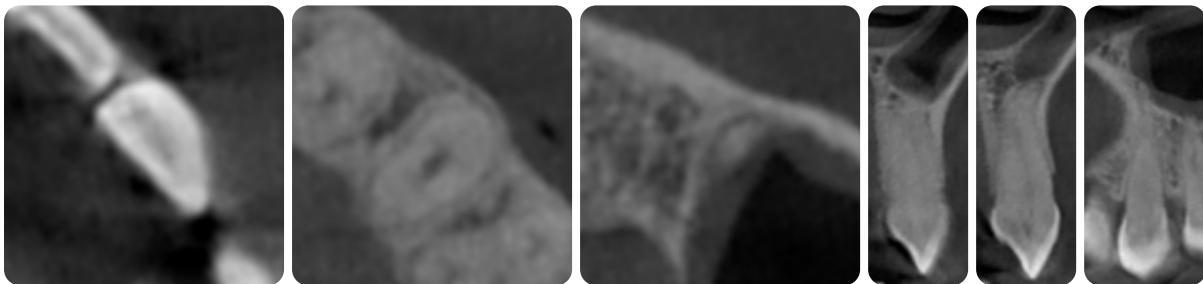
## ○ **Tooth 22**

Tooth, 1 root, 1 canal, Pulp stone



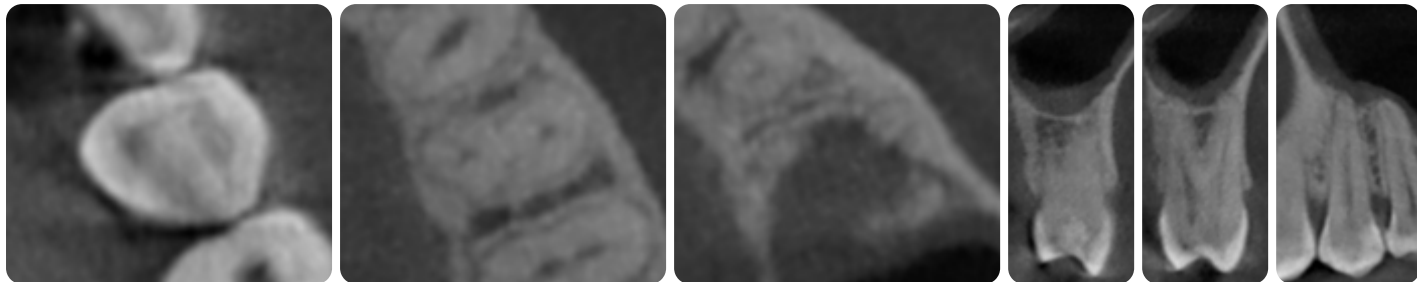
## ○ **Tooth 23**

Tooth, 1 root, 1 canal



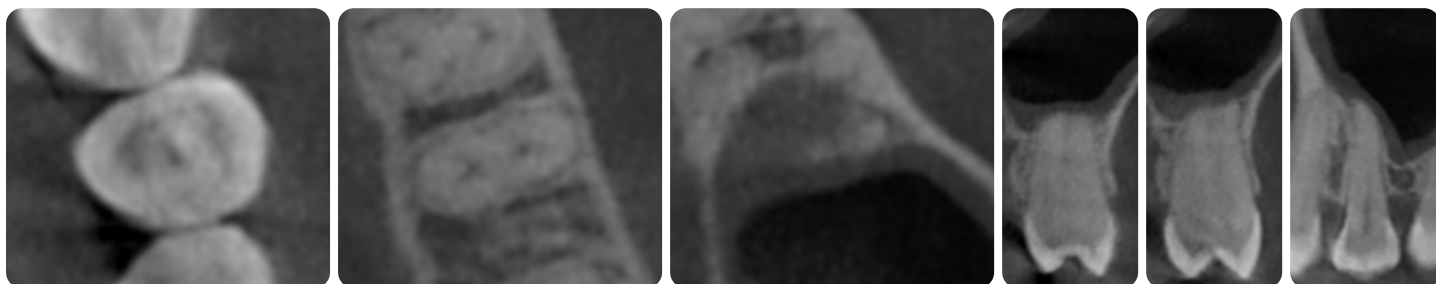
## ● Tooth 24

Tooth, Filling, 2 roots, 2 canals



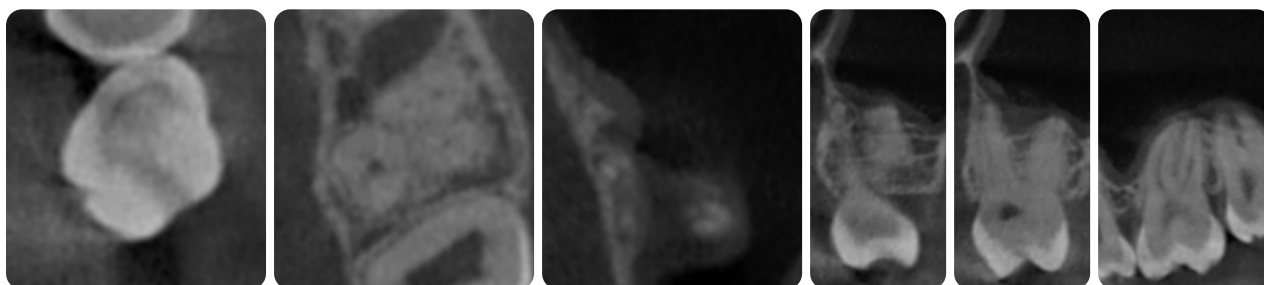
## ● Tooth 25

Tooth, 1 root, 2 canals, Caries signs (Dentin, Mesial)



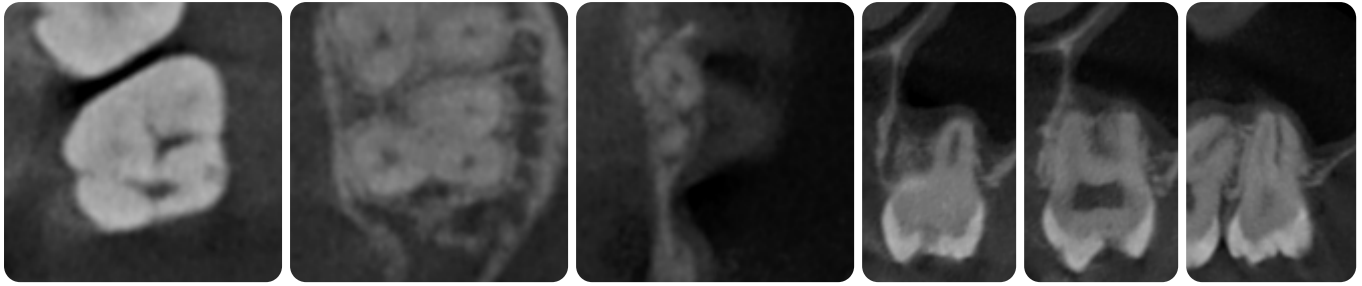
## ● Tooth 26

Tooth, Filling, 3 roots, 4 canals, Pulp stone



## ● Tooth 27

Tooth, 3 roots, 4 canals, Caries signs (Dentin, Occlusal)

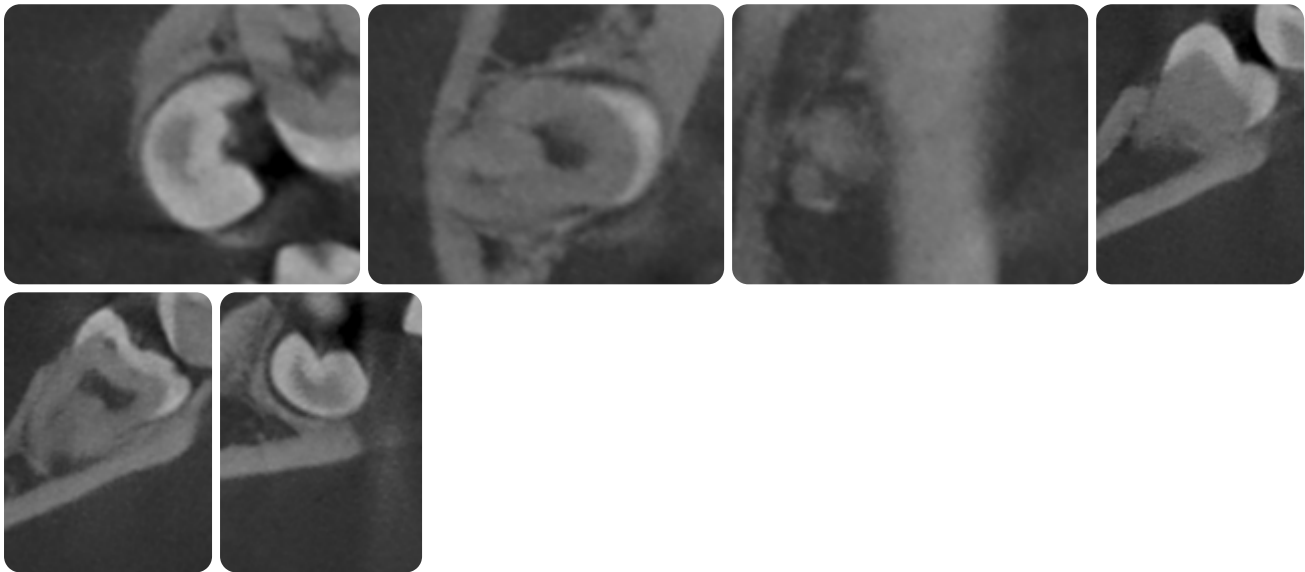


## Tooth 28

Missing

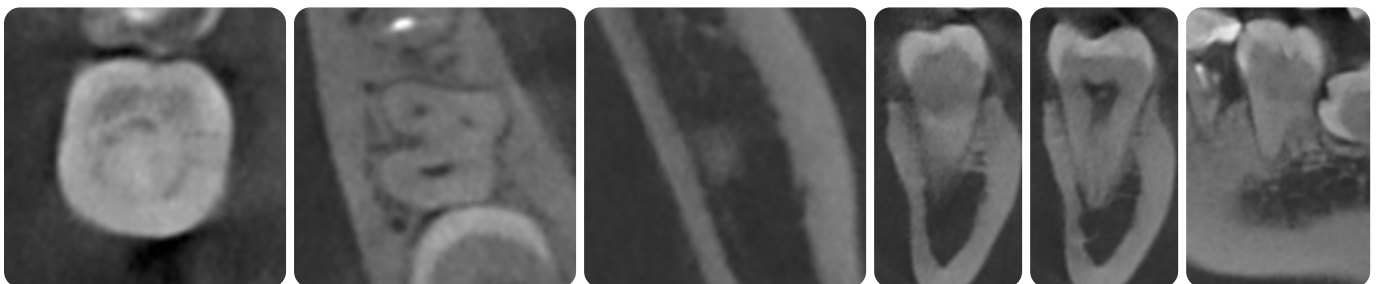
## ● Tooth 38

Tooth, Impaction, 2 roots, 3 canals



## ○ Tooth 37

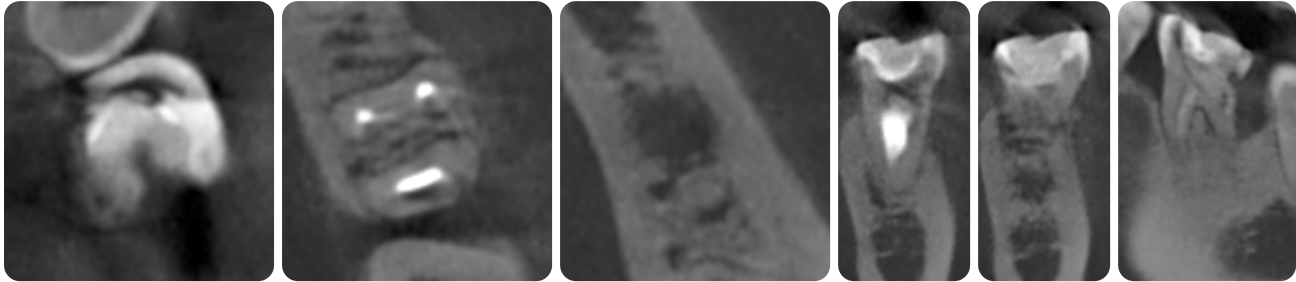
Tooth, 1 root, 3 canals





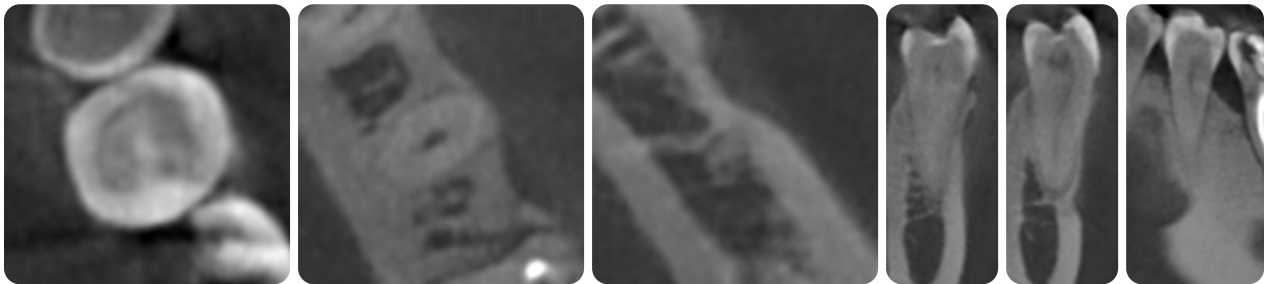
## ● Tooth 36

Tooth, Filling, 2 roots, 3 canals, Caries signs (Dentin, Root, Mesial, Distal), Endodontically treated tooth (Short filling, Adequate density), Periapical radiopacity, PDL space widening along the root, Periodontal bone loss (Moderate, Horizontal), Periapical radiolucency



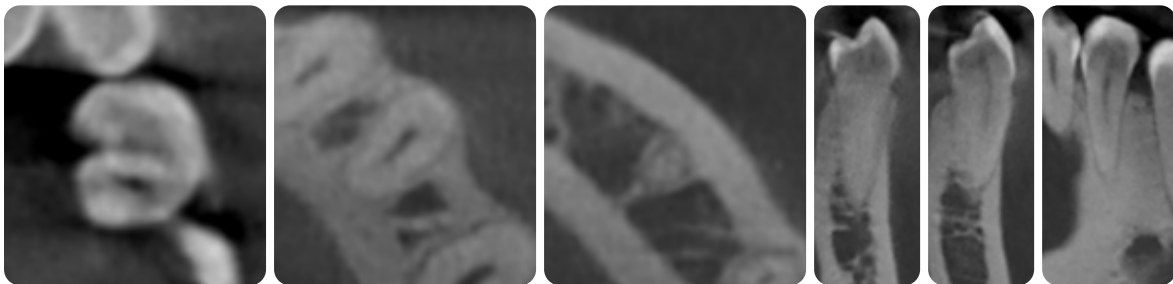
## ○ Tooth 35

Tooth, 1 root, 1 canal



## ○ Tooth 34

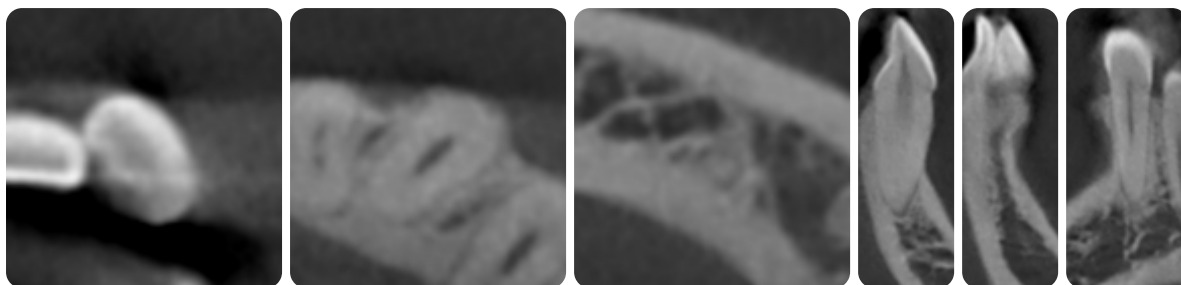
Tooth, 1 root, 1 canal





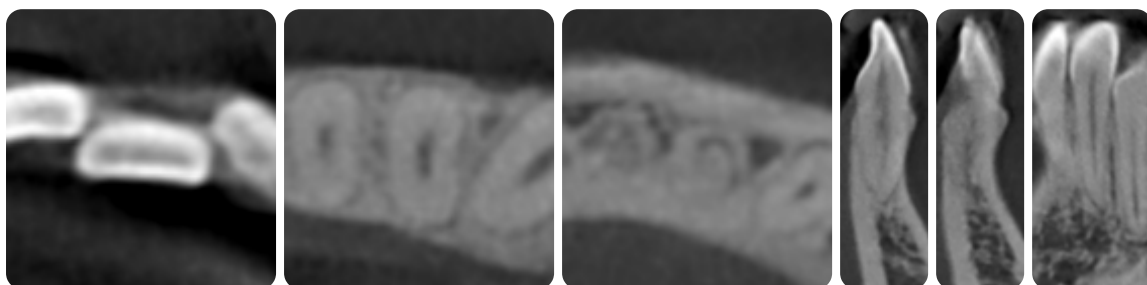
## ○ **Tooth 33**

Tooth, 1 root, 1 canal



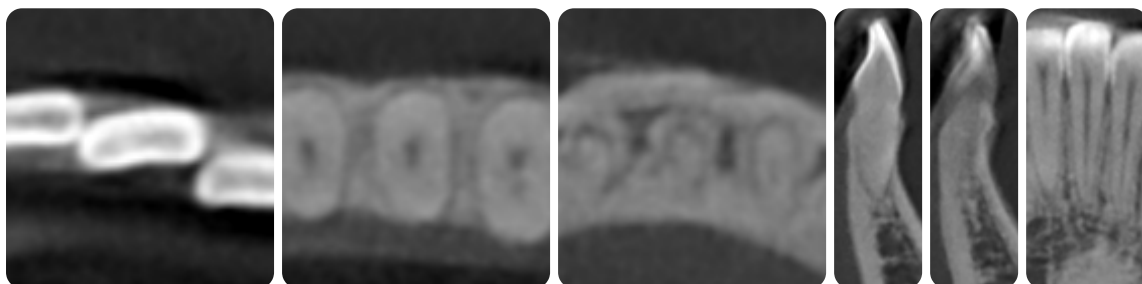
## ○ **Tooth 32**

Tooth, 1 root, 2 canals



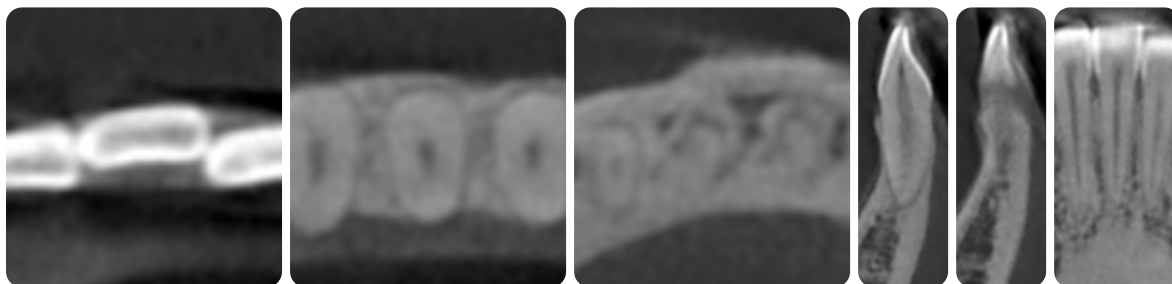
## ○ **Tooth 31**

Tooth, 1 root, 1 canal



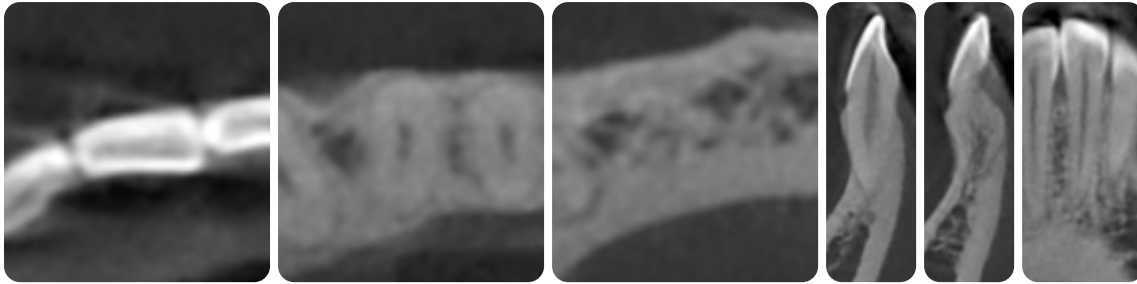
## ○ **Tooth 41**

Tooth, 1 root, 1 canal



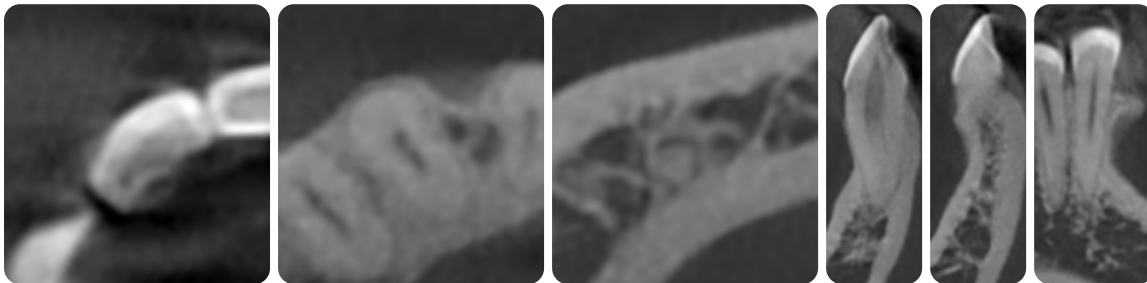
## ○ Tooth 42

Tooth, 1 root, 1 canal



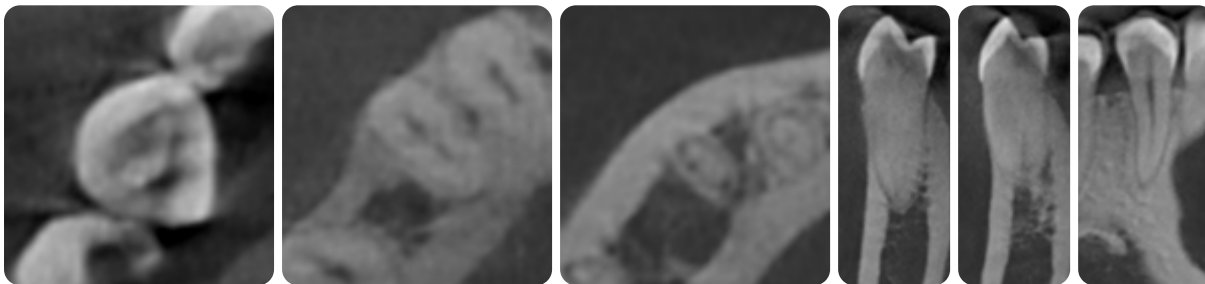
## ○ Tooth 43

Tooth, 1 root, 1 canal



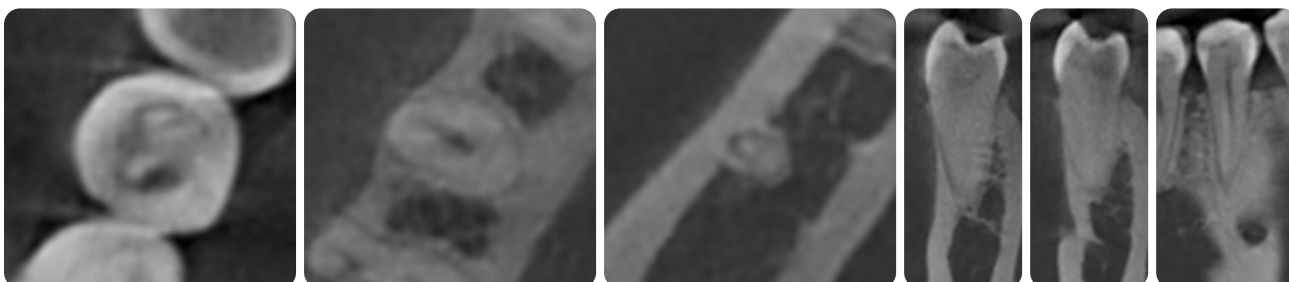
## ○ Tooth 44

Tooth, 1 root, 2 canals



## ○ Tooth 45

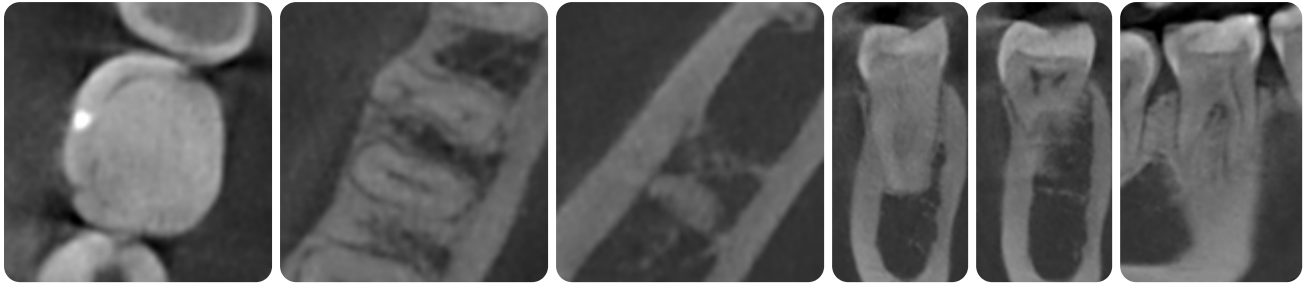
Tooth, 1 root, 1 canal



This report contains confidential health information. It was generated with Diagnocat SaaS using Artificial Intelligence. The conditions and pathologies in this report were verified by the attending dentist.

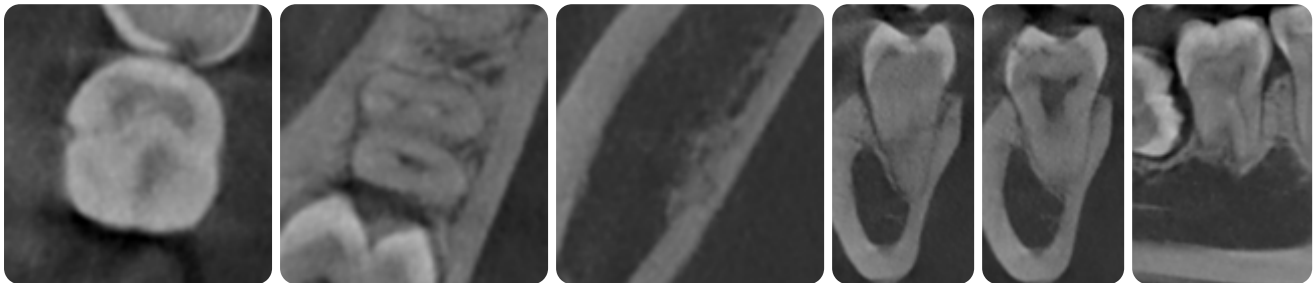
## ● Tooth 46

Tooth, Filling, 2 roots, 3 canals, Caries signs (Dentin, Mesial, Distal)



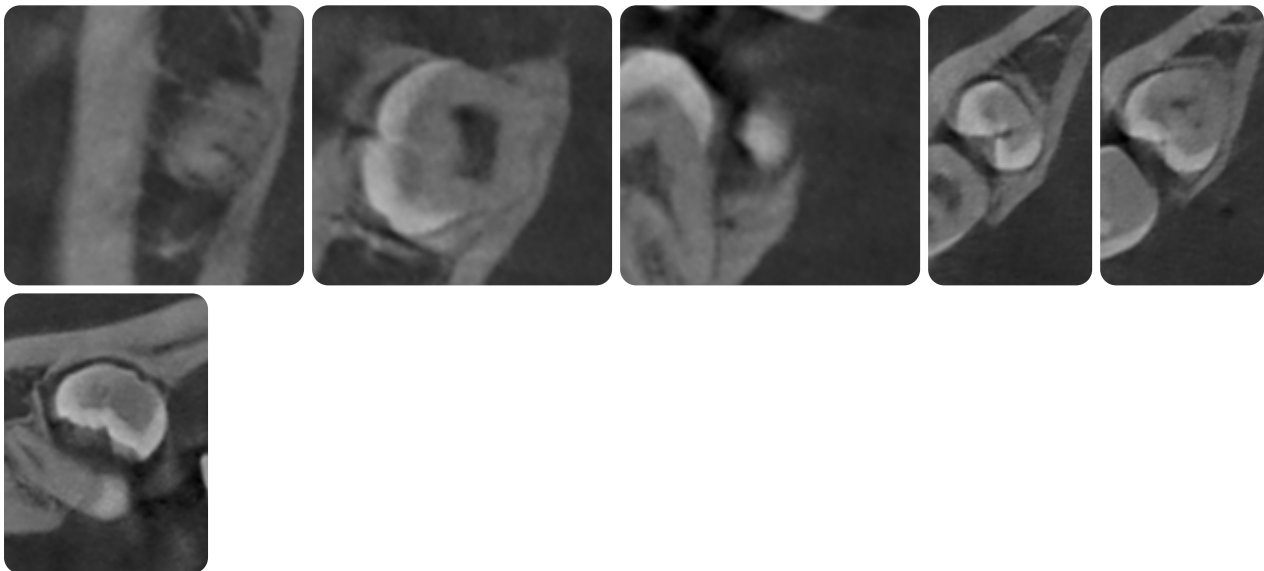
## ● Tooth 47

Tooth, Filling, 2 roots, 3 canals



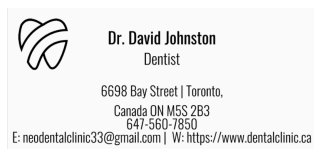## ● Tooth 48

Tooth, Impaction, 2 roots, 2 canals



Report signed: Jul 15, 2025, 10:23 AM

This report contains confidential health information. It was generated with Diagnocat SaaS using Artificial Intelligence. The conditions and pathologies in this report were verified by the attending dentist.



**Johnston David**