

## Review

# AI-Assisted CBCT Data Management in Modern Dental Practice: Benefits, Limitations and Innovations

Renáta Urban <sup>\*</sup>, Sára Haluzová, Martin Strunga , Jana Surovková , Michaela Lifková , Juraj Tomášik and Andrej Thurzo <sup>\*</sup>

Department of Orthodontics, Regenerative and Forensic Dentistry, Faculty of Medicine, Comenius University in Bratislava, 81250 Bratislava, Slovakia

<sup>\*</sup> Correspondence: urban96@uniba.sk (R.U.); thurzo3@uniba.sk (A.T.)

**Abstract:** Within the next decade, artificial intelligence (AI) will fundamentally transform the workflow of modern dental practice. This paper reviews the innovations and new roles of dental assistants in CBCT data management with the support of AI. Its use in 3D data management brings new roles for dental assistants. Cone beam computed tomography (CBCT) technology is, together with intraoral 3D scans and 3D facial scans, commonly used 3D diagnostic in a modern digital dental practice. This paper provides an overview of the potential benefits of AI implementation for semiautomated segmentations in standard medical diagnostic workflows in dental practice. It discusses whether AI tools can enable healthcare professionals to increase their reliability, effectiveness, and usefulness, and addresses the potential limitations and errors that may occur. The paper concludes that current AI solutions can improve current digital workflows including CBCT data management. Automated CBCT segmentation is one of the current trends and innovations. It can assist professionals in obtaining an accurate 3D image in a reduced period of time, thus enhancing the efficiency of the whole process. The segmentation of CBCT serves as a helpful tool for treatment planning as well as communicating the problem to the patient in an understandable way. This paper highlights a high bias risk due to the inadequate sample size and incomplete reporting in many studies. It proposes enhancing dental workflow efficiency and accuracy through AI-supported cbct data management

**Keywords:** CBCT; AI; deep learning; medical image analysis; image processing; image segmentation; dental nurse; ChatGPT; Diagnostics; Anatomage Invivo 7.0; machine learning



**Citation:** Urban, R.; Haluzová, S.; Strunga, M.; Surovková, J.; Lifková, M.; Tomášik, J.; Thurzo, A. AI-Assisted CBCT Data Management in Modern Dental Practice: Benefits, Limitations and Innovations. *Electronics* **2023**, *12*, 1710. <https://doi.org/10.3390/electronics12071710>

Academic Editors: Irena Galić, Marija Habijan, Antonio Lanata and Luca Mesin

Received: 24 February 2023

Revised: 24 March 2023

Accepted: 3 April 2023

Published: 4 April 2023



**Copyright:** © 2023 by the authors. Licensee MDPI, Basel, Switzerland. This article is an open access article distributed under the terms and conditions of the Creative Commons Attribution (CC BY) license (<https://creativecommons.org/licenses/by/4.0/>).

## 1. Introduction

Cone beam computed tomography (CBCT) is a 3D imaging technology used in dentistry for various purposes, such as implant placement, orthodontic treatment planning and root canal treatment. Currently, a lot of scientific work is being put into AI applications that focus on the automatic identification of landmarks in cone beam computed tomography [1].

Dental assistants play a crucial role in CBCT data management by preparing patients for imaging, operating the device, and assisting the dentist with image processing and interpretation. With the support of artificial intelligence (AI), dental assistants can take on new tasks in CBCT data management. The new tasks of dental assistants in CBCT data management with the support of AI can include AI-assisted image analysis, data integration and management, patient communication and education, and quality assurance. These tasks can help improve the accuracy and efficiency of CBCT imaging, leading to better treatment outcomes and more efficient dental practice. The increasing use of deep learning algorithms for segmentations [2] in medical imaging is changing the workflows in digital dental clinics [3]. For example, recent advancements in deep learning applied in CBCT in clinical applications have allowed the identification of problems including root fractures or dental implant failure predictions [4,5]. Deep learning is a subset of artificial intelligence (AI) that involves training neural networks with large amounts of data to enable them

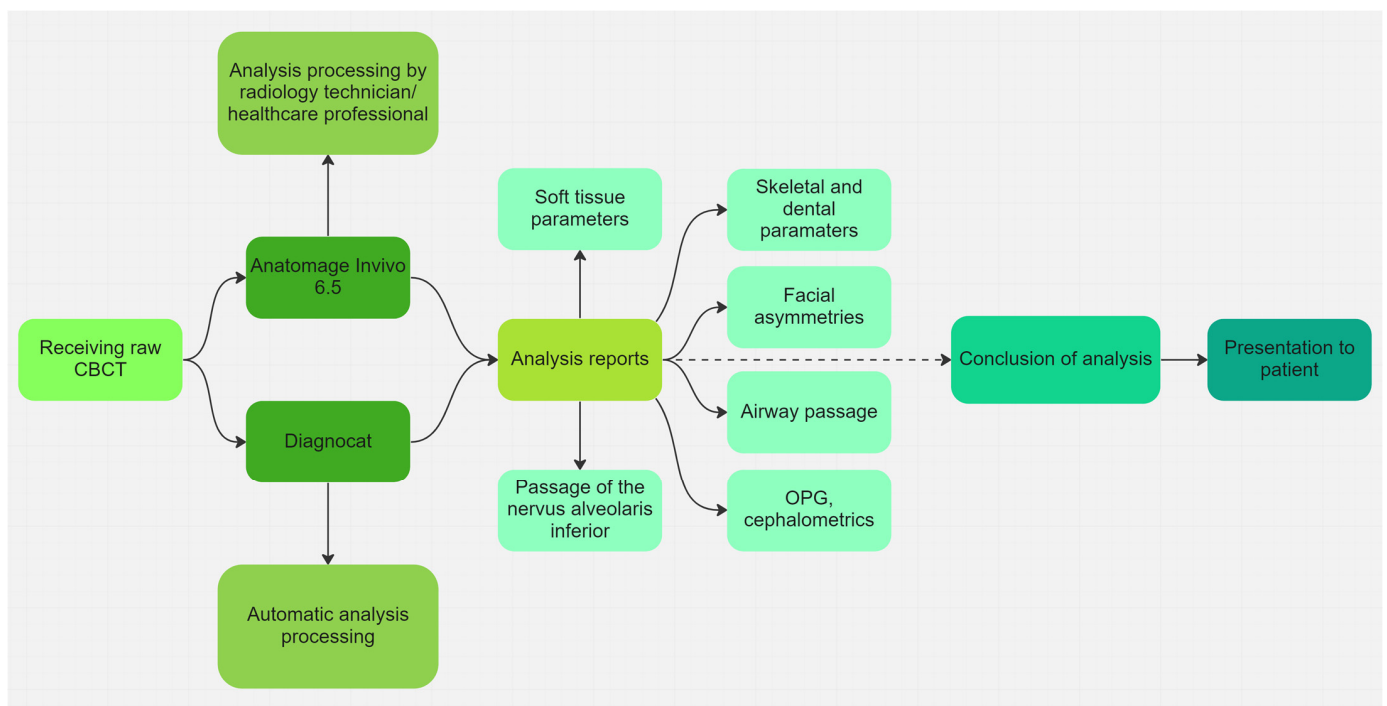
to recognize complex patterns and make predictions or decisions based on that data. In other words, deep learning is a method of teaching machines to learn and improve from experience, rather than being explicitly programmed. Medical imaging is fundamental for diagnosing, treating, and monitoring diseases and conditions, and deep learning can greatly enhance the accuracy, efficiency, and reliability of image analysis [6–10].

Deep learning is a form of artificial intelligence in which neural networks are trained to recognize patterns and make predictions. Artificial intelligence is a broader field that involves the development of intelligent machines using a variety of techniques. Advanced AI algorithms have revolutionized forensic medicine, anthropology, and clinical anatomy. The use of three-dimensional convolutional neural networks has opened up new possibilities for processing 3D medical images, including CBCT, which is represented as a sequence of 2D grayscale images [11].

There are three main groups of applications of CNN in dentistry:

1. Detecting structures (identifying the presence of normal and abnormal structures);
2. Segmenting structures (determining the exact shape of particular structures);
3. Classifying structures (distinguishing the sites and establishing the grade of a possible anomaly).

The typical process of CBCT segmentation and processing into its final form is shown on the scheme in Figure 1. Segmentation from computed tomography is not a novel process. Recently, fully convolutional networks (FCNs), most notably the UNet architecture, have greatly improved the accuracy and speed of semantic segmentation tasks, and hence medical segmentation and analysis tasks. The UNet architecture makes heavy use of contextual information [12,13]. The accurate segmentation of anatomical structures plays an important role in many clinical applications including dentistry.



**Figure 1.** Scheme of processing and segmenting CBCT into the final form and its presentation to the patient.

CBCT is a modern dental imaging system that provides fast volumetric imaging of patients with low radiation exposure. NewTom is a CBCT device designed for dental and orthodontic imaging, including surgical planning and prosthetic implants. Lascala et al. (2014) assessed the accuracy of linear measurements with NewTom. CBCT is an advancement

from 2D manual and digital analyses achieved by adding a third dimension to the diagnostic process [14,15].

CBCT is used in oral and maxillofacial surgery, endodontics, implantology, orthodontics, temporomandibular joint dysfunction, periodontology, and restorative and forensic dentistry [16,17].

Artificial intelligence algorithms aid healthcare providers in analyzing CBCT images, making diagnoses and assisting in clinical decisions [18]. Convolutional neural networks of the types of AI that are primarily utilized for the tasks of object detection and segmentation [19].

The use of DIAGNOCAT artificial intelligence can help dentists to achieve faster and more objective quality control in diagnostics and treatment. The DIAGNOCAT program acts as a medical assistant in CBCT analysis and ensures a final product of high quality. CBCT has recently become a routine imaging process, but there are significant difficulties regarding the simplification of the visualization programs. However, DIAGNOCAT's reports are clear and understandable for both physicians and patients [20].

Dentists, previously limited to two-dimensional (2D) images, can now visualize the hard tissues of the head and neck in all desired planes in 3D reconstruction. In addition, CBCT scans can reveal occult pathology and various clinically significant incidental findings located in structures outside the dentist's usual area of expertise [21].

Today's modern artificial intelligence (AI) can support the new tasks of managing CBCT data in orthodontics in several ways. Here are the examples:

1. Image segmentation: CBCT data in orthodontics usually consists of a large number of 3D images. AI algorithms can be used to segment these images, i.e., to identify and separate different anatomical structures (e.g., teeth, bone, and soft tissue) within the images. This can help orthodontists make more accurate diagnoses and treatment plans.
2. Diagnosis and treatment planning: AI can help orthodontists make more informed diagnoses and treatment plans by analyzing CBCT data and making suggestions based on patterns and trends in the data. For example, AI can identify common characteristics of patients with similar dental problems and suggest treatment options that have been proven to work in these cases.
3. Predictive analytics: AI can be used to predict the likelihood of certain outcomes based on CBCT data. For example, an AI algorithm can be trained to predict the likelihood of a successful treatment outcome for a particular patient based on their CBCT data and other clinical factors.
4. Workflow automation: AI can be used to automate certain tasks in the CBCT data management process, such as image analysis and report generation. This can help streamline the workflow and save time for orthodontic professionals.
5. Communication with the patient: AI can be used to communicate treatment options and outcomes to patients in a more visual and interactive way. For example, AI can create 3D models of patients' teeth and show them how their teeth will look like after the treatment.

The skills required for CBCT evaluation are specific to postgraduate orthodontic specialization. AI-assisted evaluations such as semiautomated 3D cephalometric analysis suggest an uncertain future as the exclusive domain of orthodontists or even humans. AI-assisted segmentation of CBCT data is already implemented in the majority of popular aligner systems showing roots from CBCT data merged with intraoral scanning such as Spark or Invisalign.

The aim of this review is to present the current impact of AI support on specialized CBCT data processing in dental offices and to inform readers of how this can transform the roles of dental assistants and nurses in the future. We specifically focus on two types of software, namely Invivo 7.0 Anatomage and Diagnocat as representants of semiautomatic and automatic programs in CBCT processing in dental practice. We assess the potential and ease of dental assistants to work with them. In addition to an evaluation of the AI-powered

CBCT management impact on the near future workflows of dental assistants and nurses, the paper discusses the limitations and risks of current AI-driven solutions applied in CBCT semiautomated processing. The novelty of this paper lies in the evaluation of current AI innovations in CBCT data processing in regard to clinical dentistry workflows and in the critical view of their current limitations.

Compared to other studies looking at AI-driven CBCT imaging, which includes the diagnosis of anatomical landmarks, pathologies and clinical effectiveness when used by dentists and their staff, several studies have evaluated older AI systems in a rapidly changing environment. The changes brought about by generative AI such as ChatGPT and others will have an impact on communication processes in dental practices. The impact of advanced AI in processing 3D data such as CBCT will open up unprecedented opportunities for dental staff, leading to new tasks and responsibilities [19,22–24].

## 2. Materials and Methods

### 2.1. Inclusion Criteria for This Scoping Review

To ensure that the review is comprehensive and relevant to the research question, inclusion criteria are based on the research question and population of interest.

- The **research question** for this scoping review is: “What are the benefits, limitations and innovations of AI-assisted CBCT data management in modern dental practice?”
- **Population of interest:** dental professionals and dental assistants involved in CBCT data management in modern dental practice.
- **Type of interventions:** the use of artificial intelligence (AI) in CBCT data management, including semiautomated segmentation and standard medical diagnostic workflows.
- **Outcomes of interest:** the benefits and limitations of AI implementation for enhancing efficiency and accuracy in CBCT data management, as well as the potential impact on the roles of dental assistants in modern dental practice. Other outcomes of interest include the reliability, effectiveness, and usefulness of AI tools in dental workflows, potential errors and limitations that may occur, and the overall impact of AI-assisted CBCT data management on the quality of patient care.

Relevant databases to search for studies were the following:

- PubMed;
- Cochrane Library;
- Scopus;
- Web of Science.

Search terms were defined as the following:

“Artificial Intelligence” OR “AI”;  
 “Cone Beam Computed Tomography” OR “CBCT”;  
 “Dental Practice” OR “Dental Workflow”;  
 “Data Management”;  
 “Semiautomated Segmentation”;  
 “Diagnostic Workflow”;  
 “Dental Assistants”;  
 “Efficiency”;  
 “Accuracy”;  
 “Reliability”;  
 “Effectiveness”;  
 “Usefulness”;  
 “Limitations”;  
 “Errors”;  
 “Patient Care”.

The search terms were combined using Boolean operators (AND, and OR) to refine the search and retrieve relevant studies.

The following inclusion criteria were used for this scoping review:

Study design: any study design;  
 Population: dental professionals or assistants or nurses;  
 Interventions: AI-assisted CBCT data management;  
 Outcomes of interest: benefits, limitations, and innovations.

Studies had to be published in English and available in full text. There were no restrictions on the date of publication. Studies that report on the use of AI in dental practice outside of CBCT data management or studies that do not address the outcomes of interest were excluded. Studies with inadequate sample sizes or incomplete reporting were also excluded.

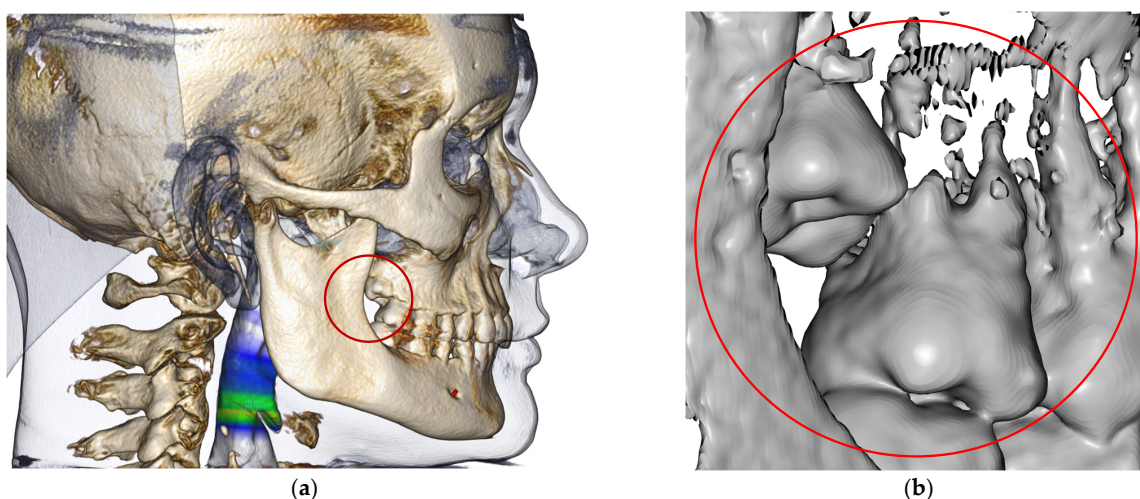
## 2.2. Software Used

The following software was used for the clinical presentation of the workflow

- Diagnocat (USA—Diagnocat LTD, Miami, FL, USA) for AI segmentation;
- Invivo 7.0 (Anatomage, Santa Clara, CA, USA) for segmented model analysis;

## 2.3. Processing CBCT

Once the CBCT data is received, the radiology technician begins to work on the preprocessing of the image for analysis. CBCT typically comes in series of grayscale DICOM images which are opened by a software; for example, Invivo 7.0 Anatomage. The task of a healthcare specialist is to prepare data for analysis or segmentation for 3D printing outputs or other workflows depending on the clinical objective. Various steps performed in CBCT are now semiautomatized and supported by the software. Manual segmentations, manual cephalometric analyses, the identification of nerve pathways or exporting panoramic views and many other tasks are now possible to be performed by a trained technician/assistant. This allows specialists such as orthodontists to focus on more complex problems. In the final form, the orthodontic specialist uses the prepared data either for cephalometric analysis, other forms of complex analysis or to construct a 3D model for the personalized modeling of appliances or accessories. The doctor reviews and then presents the data to the patient. In Figure 2, we can see the raw CBCT scan, which needs to be analyzed [25].



**Figure 2.** Example of basic processing of CBCT data in 3D visualization: (a) Automated processes allow trained dental assistant or nurse to prepare CBCT data for specialists; for example, orthodontists. Prepared data can allow some parts such as the airway or pathway of alveolar nerve to be recognized. Colors used in 3D visualization are taken from a template that aligns colors according to shade of gray from the Hounsfield scale and thus provide more didactic visualization. Region of interest shown in red circle; (b) region of interest shown in red circle is enlarged on this view. Segmentation of data images can be performed freely in opensource programs such as 3D Slicer or licensed programs such as Anatomage Medical Design Studio.

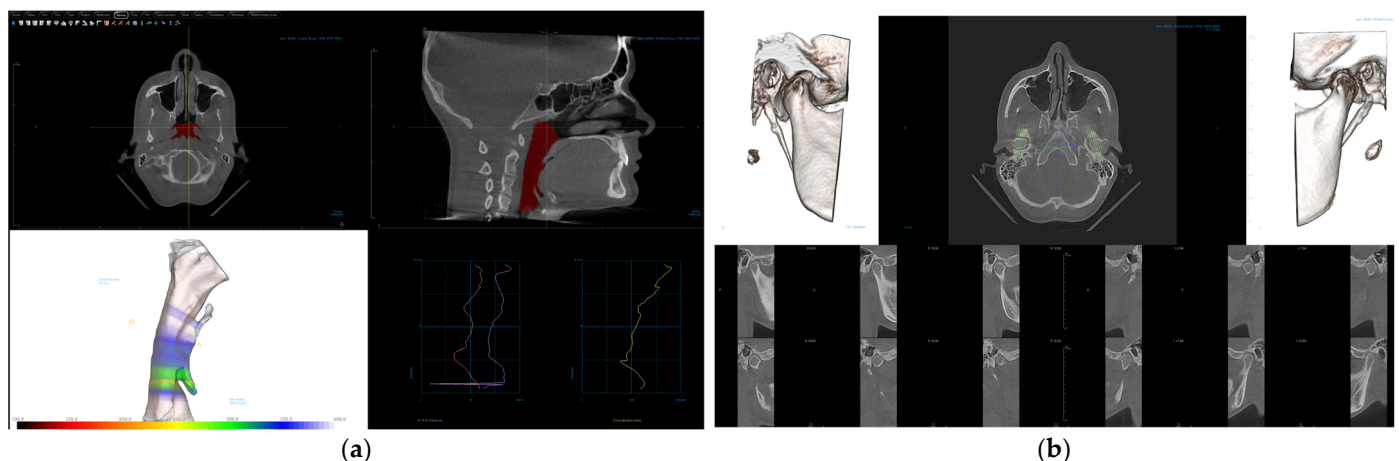


From an orthodontic point of view, we are interested in the parameters and deviations of the position of the teeth, and hard and soft tissues. Anatomage InVivo 7.0 is a semiautomatic software which, in collaboration with AI, the radiology technician can perform an analysis in which the exact parameters are calculated [26].

In our office, we process full-head X-rays as we practice face-driven orthodontics. We align teeth in such a way that is consistent with the soft tissue envelope of the patient. When necessary, we prescribe orthognathic surgery and move the hard and soft tissues into a desired position. The entire treatment outcome is based on the initial X-ray analysis combined with a 3D facial scan or photography.

From one low-dose CBCT scan, we can obtain all soft and hard tissue data of the patient. Through the Anatomage InVivo 7.0 software, we obtain the following:

- Analysis of dental parameters;
- Hard tissue analysis;
- Soft tissue analysis;
- An analysis of hard and soft tissue asymmetries;
- Passage of airways (Figure 3a);
- A cephalometric image;
- A panoramic X-ray image;
- The transition of the inferior alveolar nerve;
- The temporomandibular joint structure (Figure 3b).



**Figure 3.** Various structures are now easily visualized by semiautomated software such as Invivo 7 Anatomage. (a) Passage of the airways; (b) temporomandibular joints.

Tissue analyses tell us to what extent orthodontic treatment is necessary. They reveal the difficulty of the treatment and predict whether orthognathic surgery is necessary. The first step in the process of the analysis is to position the 3D skull accurately and to set the anatomical landmarks on the X-ray. They need to be entered manually. These points can be preset according to the different types of analyses. Usually, the landmarks include nasion, pogonion, point A, point B, Sella turcica, gonion, contours of the mandible and maxilla, outlines of incisors and molars, position of canines, etc. From all this data, a graph is created on which the differences are clearly visible. The out-of-range values are colored differently, going from green through orange to red, which is the most critical grade [27,28].

The asymmetries of the hard and soft tissues help us understand the difference between the right and left sides and to see potential underlying issues [29].

The airway passage allows us to see the extent to which it is narrowed, and we can find the exact location of the constriction. The airway is colored according to the size of the isthmus so we can determine the volume easily. It goes from green, which is a broad airway, to red, which is a constricted one. AI will calculate the exact dimensions too. Patients

with narrowed airways may suffer from obesity, diabetes, increased blood pressure, and fatigue [24,30,31].

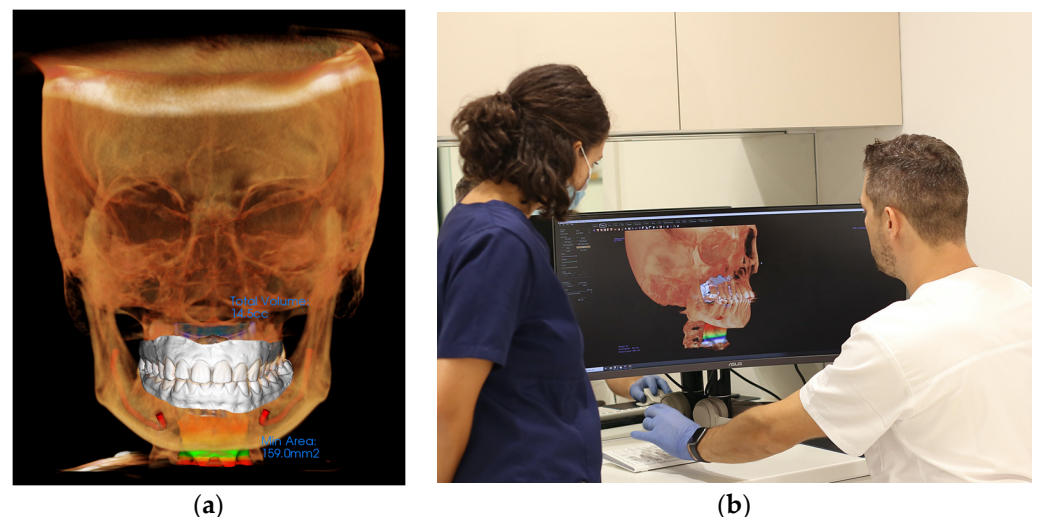
Assessing the airway volume is critical before orthognathic surgery as we can significantly improve and enlarge the passage. The study of Orhan et al. (2022) detected higher values of airway volume automatically evaluated by a different software, Diagnocat, which was caused by the software calculating the epiglottis and the posterior nasal aperture volumes too because of the low contrast of soft tissues [32].

The panoramic Image of teeth and surrounding structures can be displayed by AI after manually setting the area we want to see [33,34]. It was proven that Diagnocat identifies the periapical periodontitis more easily through CBCT compared to 2D radiographs [35].

The passage of the inferior alveolar nerve is visible on images, but with AI we can view the nerve passing through the bone in detail [36].

A TMJ image can reveal the ankylosis or destruction of the condyle. Again, AI creates a 3D model of the joint that we can look at from all angles and assess the amount of damage if it is present [37].

One of the advantages of InVivo 7.0 is that we can add a 3D scan of the face and an intraoral scan of the teeth to the image of the skull. We import the separate scans and precisely position them to the place them where they superimpose. By establishing certain points where the image and the scan should overlap, AI can then localize the scan into the final position (Figure 4a) [38].



**Figure 4.** (a) Skull model with overlapping intraoral teeth scan, passage of the airways and transition of the inferior alveolar nerve that also allowed accurately positioned placement of STL or PLY models of intraoral scanning, all managed within the workflow of trained dental nurse; (b) explaining the analysis to another doctor, to dental assistants or patient.

All the data collected is of high value so many questions can be answered with a single image. After all the analyses are completed with the help of the radiology technician and AI, the doctor can present the results to the patient or others and determine the right treatment plan—Figure 4b [39].

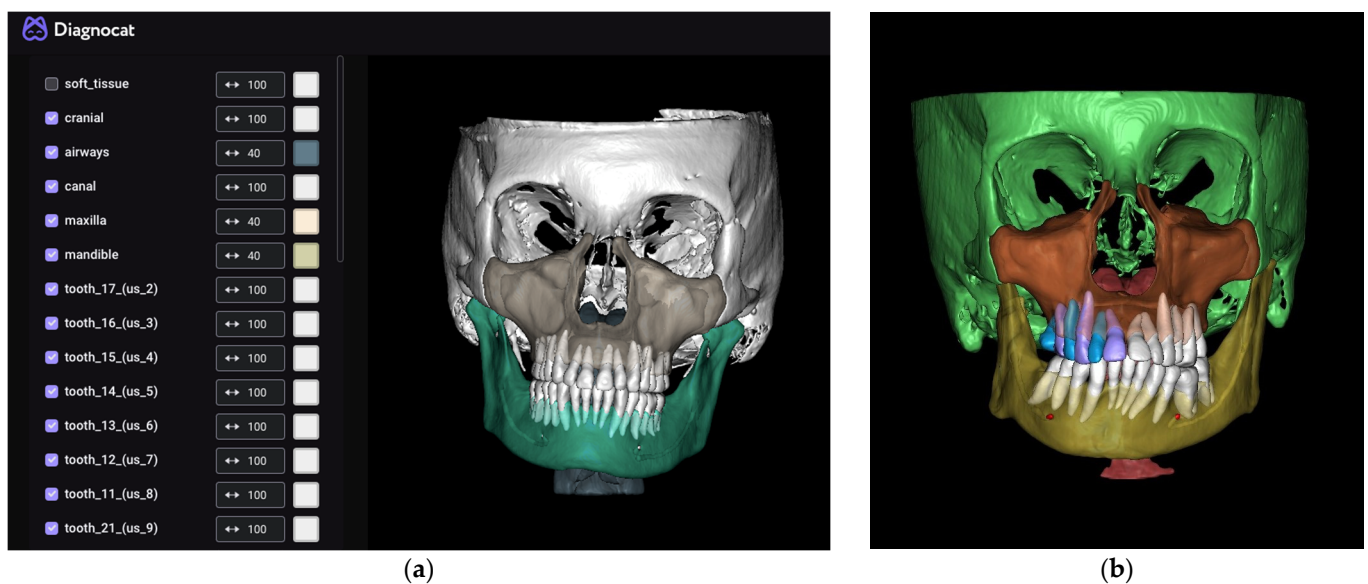
The difference between standard imaging software programs such as inViVo 7.02 and Diagnocat is that Diagnocat provides fully automatic segmentation. It is a creator of 3D STL models from 3D CBCT and DICOM files. It can simultaneously segment individual structures such as individual teeth, soft tissues, inferior alveolar nerve, mandible, maxilla, and airways. Segmentation allows the doctor to visualize anatomic features, and to localize the unerupted teeth in the bone, which can be used to calculate the force system needed to guide them to erupt in an effective way. Currently, precise calculation is not possible, because one has to consider the principles of the biologic modeling and remodeling of

bones. Although the process is demanding, this advanced software platform enables practitioners to incorporate advanced techniques into personalized treatment plans [40].

The utilization of visual aids enhances the patient's understanding of the problem and ensures a higher level of comprehension [41]. Segmentation is a useful tool of preprocessing for 3D printing and treatment planning [10,31].

Segmentation can be prepared in various softwares. InVivo 7.0 can be used to segment a 3D CBCT scan into 3D STL models too. This process takes several minutes and not everything can be segmented in detail. For example, we can segment a certain part of the mandible, but we cannot separate the individual teeth from each other. After segmenting a CBCT scan in InVivo 7.0, we have to open the 3D STL model in another program, e.g., Meshmixer, for further processing [42,43].

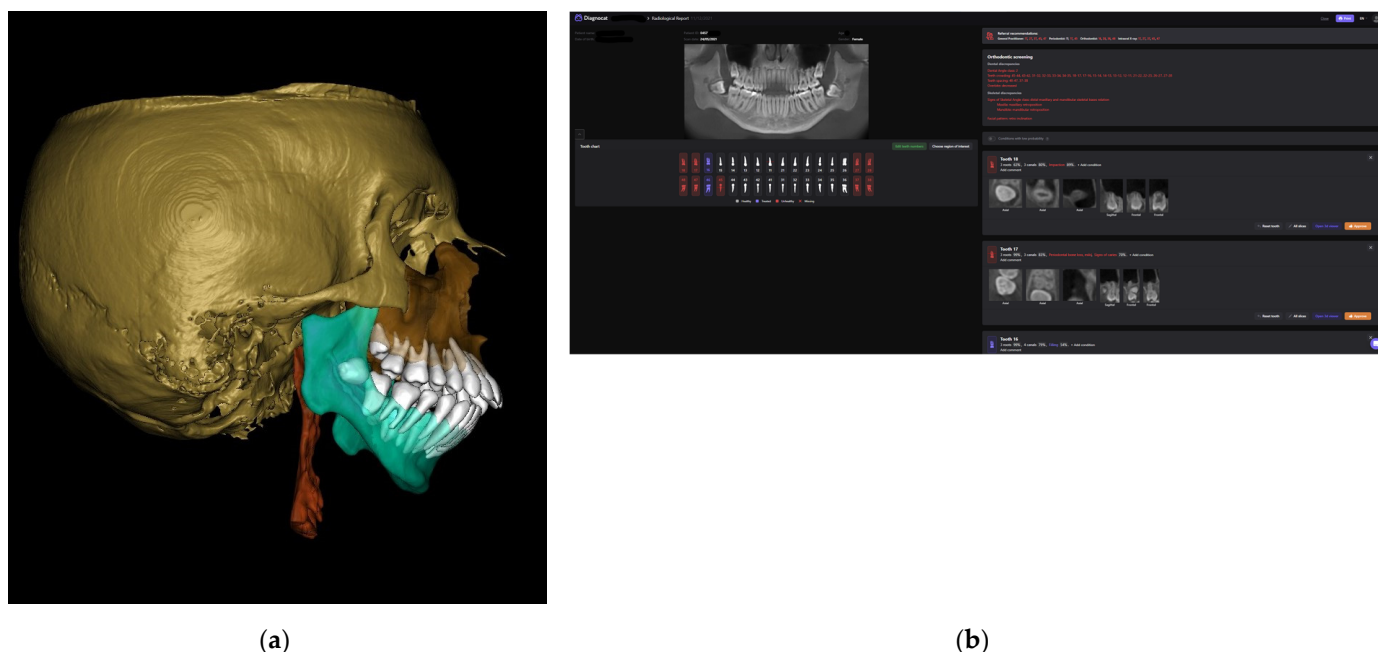
On the other hand, the Diagnocat program allows us to conduct CBCT segmentation quickly, in a matter of seconds. It is an automated process that AI is fully responsible for [11,44,45]. With the touch of a button, we can segment various head structures. Images of the teeth do not perfectly match their natural appearance, but they are very similar. Models that AI creates are free of visible artifacts. To compare, segmentation in InVivo 7.0 makes artifacts visible and often destroys the image; thus, further postprocessing in different software is needed. Figure 5a shows Diagnocat segmentation, in which various structures are automatically identified, and their opacity and color can be set (Figure 5b).



**Figure 5.** Segmentation of CBCT scan in Diagnocat software: (a) situation after fully automated CBCT segmentation, in which various structures are automatically identified, and their opacity and color can be set; (b) final result of AI-automated segmentation with various segmented structures can be exported to STLs or visualized in different colors and opacities.

In addition, Diagnocat can prepare dental and orthodontic reports and simplified analyses (Figure 6). It can also detect dental problems such as cavities, overhanging fillings, and bone loss as well as show the bone cross-section for detailed implant planning. Three-dimensional visualization enhanced with segmentation allows the patient to better understand complex medical concepts [46].





**Figure 6.** AI automated process of CBCT analysis: (a) lateral view of result of AI-automated segmentation with various segmented structures that can be exported to STLs or visualized in different colors and opacities; (b) results of AI-automated dental analysis focused on caries and other tooth or bone parameters.

### 3. Discussion

Software programs have brought many advantages that make the work of doctors, radiology technicians and healthcare professionals easier. CBCT analyses programs such as Diagnostics or Anatomage InVivo 7.0 assist in understanding pathological processes and detecting the slightest differences and abnormalities. These programs are used in the medical field for preoperative planning and simulation. They are software platforms that provide 3D representations of a patient's anatomy, which allow medical professionals to visualize the patient's specific features and plan biomechanical approaches as well as surgical procedures in a virtual environment. They increase accuracy of treatment outcome and ultimately improve patient's experience.

In the study conducted by Khabadze et al., the superior role of AI was confirmed. The authors found out that AI technologies in Diagnostics detected the proximal caries more accurately than the clinician did, although occlusal caries was diagnosed better by visual examination. On the other hand, periodontal issues were diagnosed more precisely by AI. The reports were generated significantly faster by AI than by the evaluating clinician [47].

Compared to the past, when there were only 2D images as panoramic or lateral X-rays available, we moved to a "higher level". With the use of CBCT and AI, we can accurately view airway and nerve passages, TMJ, teeth, and hard and soft tissues. Often, analysis helps us to detect even the smallest abnormalities [10,48,49]. Both software options, InVivo 7.0 and Diagnostics, obtain a similar final data set that leads physicians to the same diagnosis and treatment plan. Further study comparing the precision of manual processing with that of AI is recommended.

Based on the review, we are of an opinion that by segmenting through the Diagnostics software we can save the time and effort of healthcare professionals. Diagnostics can fully and automatically segment the CBCT file into individual anatomical structures for us. To obtain the same results with a different software would take a significantly longer time and more effort. Compared to Anatomage InVivo 7.0, in which processing takes tens of minutes depending on the dexterity of the technician, Diagnostics is ultrafast in delivering results. Segmentation in InVivo 7.0 leaves artifacts that could misrepresent the image. When

planning complex movements, artifacts are undesirable. With time and technology shifting, we can segment CBCT without a single artifact through the software [20,50]. The advantage is also the ability to segment individual teeth as this is rarely the option elsewhere.

AI segmentation of CBCT scans can be used to identify and classify different types of tissues, organs, and structures in the body. It can also detect anomalies in the body such as tumors, cysts, etc. With AI segmentation, we can compare changes in the body over time [10,51,52]. AI automated segmentation can dramatically improve forensic aspects of age assessment and other forensic analyses from X-ray diagnostics [44,53]. AI assistance is changing patient–doctor communication [54] as well as smart app patient tools [55]. AI-automated CBCT segmentation provides facial surface data that can be approximated to soft tissue facial scans [31], and automated AI segmentation paves the way for semiautomated personalized device design, which currently requires a lot of human effort [31,56].

This technology can help doctors to monitor the progress of a patient's condition and adjust their treatment plan accordingly. It is important to keep in mind that the ease of performing segmentation can also depend on the specific needs and requirements of the user, such as the type of medical imaging being used, the intended use of the segmented image, and the level of accuracy needed. It may be necessary to try multiple software platforms or to seek assistance from experienced users before finding the one that is easiest to use for a specific task [57–59].

AI is regularly used in the processing and analysis of CBCT in dentistry [60]. AI algorithms such as Diagnocat have been developed to perform coarse to fine volumetric segmentation of teeth in CBCT images, which are efficient in processing large data sets [19]. Diagnocat's artificial intelligence analyzes the acquired CBCT images in a DICOM format and enables smooth data transfer [32,61]. The AI-driven dental imaging software can help process the data quickly and efficiently [60,62].

The benefits of AI in medical diagnostics aimed at assessing CBCT scans include the improved accuracy, speed and efficiency of diagnosis [62]. However, there are limitations to the AI processing of CBCT scans, such as the low reliability in some parameters that include AI algorithms affected by metallic artifacts [24,63], variations in canal calcifications, errors due to examiner experience [64] and minimal cross-sectional areas [63,65]. The effectiveness, utility and limitations of the AI processing of CBCT depend on various factors such as the quality of the data used, the design of the algorithm and the training data [65]. In the recent assessments of the accuracy of AI-driven automated detection of small edentulous regions in CBCT, the AI algorithms were fast and highly accurate at detecting teeth and small edentulous regions, tooth labeling was up to six times faster and segmentation was conducted up to 900 times faster than it was by an experienced dental surgeon [23,65].

There are several limitations of AI processing of CBCT data [22] that can be divided into two main groups.

Firstly, the quality assessment of the literature suggests that there is a high risk of bias in many of the relevant studies. Inadequate sample sizes and incomplete reporting are the main contributors to the high risk of bias.

Secondly, there have been a variety of applications that are very heterogeneous in terms of AI techniques, dataset acquisition and analysis, and performance metrics, making comparisons difficult.

The assessment of the quality of the literature indicates a high risk of bias due to the inadequate sample size and incomplete reporting in many studies. High-quality annotated datasets and external validation are needed to improve AI-based dental imaging. Applications are diverse, making comparisons difficult. AI can improve dental care, but further research and validation are needed before its clinical use, especially in view of the limited availability of data [22,23,63,65].

#### 4. Conclusions

The conclusions of this review suggest that dental assistants play a key role in dental CBCT data management in the office, not only by preparing patients for imaging and

operating the device, but also by assisting the dentist with image interpretation and data preparation. With the support of artificial intelligence (AI), dental assistants can take on new tasks in CBCT data management:

- AI-assisted image processing and analysis; AI algorithms can be trained to analyze CBCT images for specific dental conditions, such as by identifying the location and alignment of impacted teeth or assessing bone quality for implant placement.
- Data integration and management; CBCT data can be integrated with other patient data, such as intraoral scans and electronic dental records, to provide a comprehensive overview of the patient's dental health.
- Patient communication and education; AI tools can help dental assistants communicate CBCT findings clearly to patients, helping them better understand their dental health and treatment options.
- Quality assurance; AI algorithms can be used to ensure the quality of CBCT images, such as by detecting artifacts or image distortions that could affect image interpretation.
- The assessment of the quality of the literature indicates a high risk of bias due to the inadequate sample size and incomplete reporting in many studies. High-quality annotated datasets and external validation are needed to improve AI-based dental imaging. AI can improve dental care, but further research and validation are needed before its clinical use, especially in view of the limited availability of data.

**Author Contributions:** Conceptualization, A.T., S.H., M.S., R.U. and J.S.; methodology, A.T.; software, A.T.; validation, A.T., S.H., M.S., R.U. and J.S.; formal analysis, A.T.; investigation, S.H.; resources, A.T.; data curation, A.T.; writing—original draft preparation, A.T., S.H., M.S., R.U. and J.S.; writing—review and editing, A.T., M.L., J.T., S.H., M.S., R.U. and J.S.; visualization, S.H.; supervision, A.T.; project administration, A.T.; funding acquisition, A.T. All authors have read and agreed to the published version of the manuscript.

**Funding:** This work was supported by the Slovak Grant Agency for Science KEGA Thurzo, grant number 054UK-4/2023 and APVV-22-0381.

**Institutional Review Board Statement:** Not applicable.

**Data Availability Statement:** Not applicable.

**Acknowledgments:** The authors gratefully acknowledge the technological support of the digital dental lab infrastructure of 3Dent Medical Ltd. as well as the dental clinic Sangre Azul Ltd.

**Conflicts of Interest:** The authors declare no conflict of interest.

## References

1. Gillot, M.; Miranda, F.; Baquero, B.; Ruellas, A.; Gurgel, M.; al Turkestani, N.; Anchling, L.; Hutin, N.; Biggs, E.; Yatabe, M.; et al. Automatic Landmark Identification in Cone-Beam Computed Tomography. *Orthod. Craniofacial Res.* **2023**. [\[CrossRef\]](#)
2. Benčević, M.; Galić, I.; Habijan, M.; Pižurica, A. Recent Progress in Epicardial and Pericardial Adipose Tissue Segmentation and Quantification Based on Deep Learning: A Systematic Review. *Appl. Sci.* **2022**, *12*, 5217. [\[CrossRef\]](#)
3. Singh, S.P.; Wang, L.; Gupta, S.; Goli, H.; Padmanabhan, P.; Gulyás, B. 3D Deep Learning on Medical Images: A Review. *Sensors* **2020**, *20*, 5097. [\[CrossRef\]](#) [\[PubMed\]](#)
4. Yang, P.; Guo, X.; Mu, C.; Qi, S.; Li, G. Detection of Vertical Root Fractures by Cone-Beam Computed Tomography Based on Deep Learning. *Dentomaxillofacial Radiol.* **2023**, *52*, 20220345. [\[CrossRef\]](#) [\[PubMed\]](#)
5. Zhang, C.; Fan, L.; Zhang, S.; Zhao, J.; Gu, Y. Deep Learning Based Dental Implant Failure Prediction from Periapical and Panoramic Films. *Quant. Imaging Med. Surg.* **2023**, *13*, 935–945. [\[CrossRef\]](#) [\[PubMed\]](#)
6. Singh, N.K.; Raza, K. Progress in Deep Learning-Based Dental and Maxillofacial Image Analysis: A Systematic Review. *Expert Syst. Appl.* **2022**, *199*, 116968. [\[CrossRef\]](#)
7. Murata, M.; Arij, Y.; Ohashi, Y.; Kawai, T.; Fukuda, M.; Funakoshi, T.; Kise, Y.; Nozawa, M.; Katsumata, A.; Fujita, H.; et al. Deep-Learning Classification Using Convolutional Neural Network for Evaluation of Maxillary Sinusitis on Panoramic Radiography. *Oral Radiol.* **2019**, *35*, 301–307. [\[CrossRef\]](#)
8. Lee, J.H.; Kim, D.H.; Jeong, S.N.; Choi, S.H. Detection and Diagnosis of Dental Caries Using a Deep Learning-Based Convolutional Neural Network Algorithm. *J. Dent.* **2018**, *77*, 106–111. [\[CrossRef\]](#)
9. Fatima, A.; Shahid, A.R.; Raza, B.; Madni, T.M.; Janjua, U.I. State-of-the-Art Traditional to the Machine- and Deep-Learning-Based Skull Stripping Techniques, Models, and Algorithms. *J. Digit. Imaging* **2020**, *33*, 1443–1464. [\[CrossRef\]](#)

10. Wang, H.; Minnema, J.; Batenburg, K.J.; Forouzanfar, T.; Hu, F.J.; Wu, G. Multiclass CBCT Image Segmentation for Orthodontics with Deep Learning. *J. Dent. Res.* **2021**, *100*, 943–949. [\[CrossRef\]](#)
11. Thurzo, A.; Kosnáčová, H.S.; Kurilová, V.; Kosmel', S.; Beňuš, R.; Moravanský, N.; Kováč, P.; Kuracinová, K.M.; Palkovič, M.; Varga, I. Use of Advanced Artificial Intelligence in Forensic Medicine, Forensic Anthropology and Clinical Anatomy. *Healthcare* **2021**, *9*, 1545. [\[CrossRef\]](#) [\[PubMed\]](#)
12. Habijan, M.; Galić, I.; Romić, K.; Leventić, H. AB-ResUNet+: Improving Multiple Cardiovascular Structure Segmentation from Computed Tomography Angiography Images. *Appl. Sci.* **2022**, *12*, 3024. [\[CrossRef\]](#)
13. Habijan, M.; Leventić, H.; Galić, I.; Babin, D. Neural Network Based Whole Heart Segmentation from 3D CT Images. *Int. J. Electr. Comput. Eng. Syst.* **2020**, *11*, 25–31. [\[CrossRef\]](#)
14. Lascala, C.A.; Panella, J.; Marques, M.M. Analysis of the Accuracy of Linear Measurements Obtained by Cone Beam Computed Tomography (CBCT-NewTom). *Dentomaxillofacial Radiol.* **2014**, *33*, 291–294. [\[CrossRef\]](#) [\[PubMed\]](#)
15. Thurzo, A.; Javorka, V.; Stanko, P.; Lysy, J.; Suchancova, B.; Lehotska, V.; Valkovic, L.; Makovnik, M. Digital and Manual Cephalometric Analysis. *Bratisl. Med. J.* **2010**, *111*, 97–100.
16. Alamri, H.M.; Sadrameli, M.; Alshalhoob, M.A.; Sadrameli, M.; Alshehri, M.A. Applications of CBCT in Dental Practice: A Review of the Literature. *Gen. Dent.* **2012**, *60*, 390–400.
17. Chen, Y.-W.; Stanley, K.; Att, W.; Dent, M. Artificial Intelligence in Dentistry: Current Applications and Future Perspectives. *Quintessence Int.* **2020**, *51*, 248–257. [\[CrossRef\]](#)
18. Palanivel, J.; Davis, D.; Srinivasan, D.; Nc, S.C.; Kalidass, P.; Kishore, S.; Suvetha, S. Artificial Intelligence—Creating the Future in Orthodontics—A Review. *J. Evol. Med. Dent. Sci.* **2021**, *10*, 2108–2113. [\[CrossRef\]](#)
19. Ezhov, M.; Gusarev, M.; Golitsyna, M.; Yates, J.M.; Kushnerev, E.; Tamimi, D.; Aksoy, S.; Shumilov, E.; Sanders, A.; Orhan, K. Clinically Applicable Artificial Intelligence System for Dental Diagnosis with CBCT. *Sci. Rep.* **2021**, *11*, 15006. [\[CrossRef\]](#)
20. Ghazal, J. *Application of Artificial Intelligence Diagnostoc in Diagnostics of Maxillary Sinusitis*; Boiarina, Ed.; Belarusian State Medical University: Minsk, Belarus, 2021; Volume 1, p. 1330. ISBN 978-985-21-0765-5.
21. Benavides, E.; Edwards, P.C. Detection of Incidental Findings in Cone Beam Computed Tomography Imaging and Their Clinical Implications. *Cone Beam Comput. Tomogr. Orthod. Indic. Insights Innov.* **2014**, 185–219. [\[CrossRef\]](#)
22. Mureşanu, S.; Almăşan, O.; Hedeşiu, M.; Dioşan, L.; Dinu, C.; Jacobs, R. Artificial Intelligence Models for Clinical Usage in Dentistry with a Focus on Dentomaxillofacial CBCT: A Systematic Review. *Oral Radiol.* **2023**, *39*, 18–40. [\[CrossRef\]](#)
23. Gerhardt, M.D.N.; Fontenele, R.C.; Willems, H.; Jacobs, R. Accuracy of an Artificial Intelligence-Driven Tool for the Detection of Small Edentulous Regions on Cone-Beam Computed Tomography. *J. Dent.* **2022**, *121*, 103989. [\[CrossRef\]](#)
24. Tsolakis, I.A.; Kolokitha, O.-E.; Papadopoulou, E.; Tsolakis, A.I.; Kilipiris, E.G.; Palomo, J.M. Artificial Intelligence as an Aid in CBCT Airway Analysis: A Systematic Review. *Life* **2022**, *12*, 1894. [\[CrossRef\]](#) [\[PubMed\]](#)
25. Aung, N.M.; Myint, K.K. Diagnostic Accuracy of CBCT for Detection of Second Canal of Permanent Teeth: A Systematic Review and Meta-Analysis. *Int. J. Dent.* **2021**, *2021*, 1107471. [\[CrossRef\]](#)
26. Olczak, K.; Pawlicka, H.; Szymański, W. Root and Canal Morphology of the Maxillary Second Premolars as Indicated by Cone Beam Computed Tomography. *Aust. Endod. J.* **2022**. [\[CrossRef\]](#) [\[PubMed\]](#)
27. Alhammadi, M.S.; Al-mashraqi, A.A.; Alnami, R.H.; Ashqar, N.M.; Alamir, O.H.; Halboub, E.; Reda, R.; Testarelli, L.; Patil, S. Accuracy and Reproducibility of Facial Measurements of Digital Photographs and Wrapped Cone Beam Computed Tomography (CBCT) Photographs. *Diagnostics* **2021**, *11*, 757. [\[CrossRef\]](#)
28. Vasiljevic, M.; Milanovic, P.; Jovicic, N.; Vasovic, M.; Milovanovic, D.; Vojinovic, R.; Selakovic, D.; Rosic, G. Morphological and Morphometric Characteristics of Anterior Maxilla Accessory Canals and Relationship with Nasopalatine Canal Type—A CBCT Study. *Diagnostics* **2021**, *11*, 1510. [\[CrossRef\]](#)
29. Leonardi, R.; Ronsivalle, V.; Lagravere, M.O.; Barbato, E.; Isola, G.; lo Giudice, A. Three-Dimensional Assessment of the Spheno-Occipital Synchondrosis and Clivus after Tooth-Borne and Bone-Borne Rapid Maxillary Expansion. *Angle Orthod.* **2021**, *91*, 822–829. [\[CrossRef\]](#)
30. Dong, Q.; Shi, H.; Jia, Q.; Tian, Y.; Zhi, K.; Zhang, L. Analysis of Three-Dimensional Morphological Differences in the Mandible between Skeletal Class I and Class II with CBCT Fixed-Point Measurement Method. *Scanning* **2021**, *2021*, 9996857. [\[CrossRef\]](#)
31. Thurzo, A.; Šufliarsky, B.; Urbanová, W.; Čverha, M.; Strunga, M.; Varga, I. Pierre Robin Sequence and 3D Printed Personalized Composite Appliances in Interdisciplinary Approach. *Polymers* **2022**, *14*, 3858. [\[CrossRef\]](#)
32. Orhan, K.; Shamshiev, M.; Ezhov, M.; Plaksin, A.; Kurbanova, A.; Ünsal, G.; Gusarev, M.; Golitsyna, M.; Aksoy, S.; Mısırlı, M.; et al. AI-Based Automatic Segmentation of Craniomaxillofacial Anatomy from CBCT Scans for Automatic Detection of Pharyngeal Airway Evaluations in OSA Patients. *Sci. Rep.* **2022**, *12*, 11863. [\[CrossRef\]](#) [\[PubMed\]](#)
33. Almalki, Y.E.; Din, A.I.; Ramzan, M.; Irfan, M.; Aamir, K.M.; Almalki, A.; Alotaibi, S.; Alaglan, G.; Alshamrani, H.A.; Rahman, S. Deep Learning Models for Classification of Dental Diseases Using Orthopantomography X-ray OPG Images. *Sensors* **2022**, *22*, 7370. [\[CrossRef\]](#)
34. Opris, H.; Baciut, M.; Bran, S.; Onisor, F.; Almasan, O.; Manea, A.; Tamas, T.; Stoia, S.; Gabriel, A.; Baciut, G.; et al. Lateral Cephalometric Analytical Uses for Temporomandibular Joint Disorders: The Importance of Cervical Posture and Hyoid Position. *Int. J. Environ. Res. Public Health* **2022**, *19*, 11077. [\[CrossRef\]](#) [\[PubMed\]](#)
35. Zadrożny, Ł.; Regulski, P.; Brus-Sawczuk, K.; Czajkowska, M.; Parkanyi, L.; Ganz, S.; Mijiritsky, E. Artificial Intelligence Application in Assessment of Panoramic Radiographs. *Diagnostics* **2022**, *12*, 224. [\[CrossRef\]](#) [\[PubMed\]](#)



36. Lupi, S.M.; Landini, J.; Olivieri, G.; Todaro, C.; Scribante, A.; Rodriguez y Baena, R. Correlation between the Mandibular Lingula Position and Some Anatomical Landmarks in Cone Beam CT. *Healthcare* **2021**, *9*, 1747. [\[CrossRef\]](#)
37. Patel, A.R.; Vathare, A.; Mall, P.; Ghunawat, D.B.; Thole, L.; Dhande, P.; Kulkarni, D. Correlation between Clinical Symptoms and Cone Beam Computed Tomography Finding in Temporomandibular Disorders Patients. *Int. J. Health Sci.* **2022**, *6*, 2381–2387. [\[CrossRef\]](#)
38. Thurzo, A.; Strunga, M.; Havlínová, R.; Reháková, K.; Urban, R.; Surovková, J.; Kurilová, V. Smartphone-Based Facial Scanning as a Viable Tool for Facially Driven Orthodontics? *Sensors* **2022**, *22*, 7752. [\[CrossRef\]](#) [\[PubMed\]](#)
39. Lee, S.-C.; Hwang, H.-S.; Lee, K.C. Accuracy of Deep Learning-Based Integrated Tooth Models by Merging Intraoral Scans and CBCT Scans for 3D Evaluation of Root Position during Orthodontic Treatment. *Prog. Orthod.* **2022**, *23*, 15. [\[CrossRef\]](#)
40. Retrouvey, J.-M.; Conley, R.S. Decoding Deep Learning Applications for Diagnosis and Treatment Planning. *Dent. Press J. Orthod.* **2022**, *27*, 22–27. [\[CrossRef\]](#)
41. Issa, J.; Olszewski, R.; Dyszkiewicz-Konwińska, M. The Effectiveness of Semi-Automated and Fully Automatic Segmentation for Inferior Alveolar Canal Localization on CBCT Scans: A Systematic Review. *Int. J. Environ. Res. Public Health* **2022**, *19*, 560. [\[CrossRef\]](#)
42. D'Addazio, G.; Xhajanka, E.; Traini, T.; Santilli, M.; Rexhepi, I.; Murmura, G.; Caputi, S.; Sinjari, B. Accuracy of DICOM–DICOM vs. DICOM–STL Protocols in Computer-Guided Surgery: A Human Clinical Study. *J. Clin. Med.* **2022**, *11*, 2336. [\[CrossRef\]](#)
43. da Silva Rocha, É.; Endo, P.T. A Comparative Study of Deep Learning Models for Dental Segmentation in Panoramic Radiograph. *Appl. Sci.* **2022**, *12*, 3103. [\[CrossRef\]](#)
44. Thurzo, A.; Jančovičová, V.; Hain, M.; Thurzo, M.; Novák, B.; Kosnáčová, H.; Lehotská, V.; Moravanský, N.; Varga, I. Human Remains Identification Using Micro-CT, Spectroscopic and A.I. Methods in Forensic Experimental Reconstruction of Dental Patterns After Concentrated Acid Significant Impact. *Molecules* **2022**, *27*, 4035. [\[CrossRef\]](#) [\[PubMed\]](#)
45. Strunga, M.; Urban, R.; Surovková, J.; Thurzo, A. Artificial Intelligence Systems Assisting in the Assessment of the Course and Retention of Orthodontic Treatment. *Healthcare* **2023**, *11*, 683. [\[CrossRef\]](#)
46. Kurt Bayrakdar, S.; Orhan, K.; Bayrakdar, I.S.; Bilgir, E.; Ezhov, M.; Gusarev, M.; Shumilov, E. A Deep Learning Approach for Dental Implant Planning in Cone-Beam Computed Tomography Images. *BMC Med. Imaging* **2021**, *21*, 86. [\[CrossRef\]](#) [\[PubMed\]](#)
47. Khabadze, Z.; Makeeva, I.; Mordanov, O.; Nazarova, D. Processing of cbct data with artificial intelligence in the diagnosis of caries and its complications. *Actual Probl. Dent.* **2022**, *18*, 78–86. [\[CrossRef\]](#)
48. Izham, A.; Auerkari, E.I. The Use of Radiology CBCT in Odontology Forensic. *AIP Conf. Proc.* **2021**, *2344*, 050012. [\[CrossRef\]](#)
49. Kim, S.-H.; Kim, K.B.; Choo, H. New Frontier in Advanced Dentistry: CBCT, Intraoral Scanner, Sensors, and Artificial Intelligence in Dentistry. *Sensors* **2022**, *22*, 2942. [\[CrossRef\]](#)
50. Qiu, B.; van der Wel, H.; Kraeima, J.; Glas, H.H.; Guo, J.; Borra, R.J.H.; Witjes, M.J.H.; van Ooijen, P.M.A. Robust and Accurate Mandible Segmentation on Dental CBCT Scans Affected by Metal Artifacts Using a Prior Shape Model. *J. Pers. Med.* **2021**, *11*, 364. [\[CrossRef\]](#)
51. Duman, Ş.B.; Syed, A.Z.; Celik Ozen, D.; Bayrakdar, İ.Ş.; Salehi, H.S.; Abdelkarim, A.; Celik, Ö.; Eser, G.; Altun, O.; Orhan, K. Convolutional Neural Network Performance for Sella Turcica Segmentation and Classification Using CBCT Images. *Diagnostics* **2022**, *12*, 2244. [\[CrossRef\]](#)
52. Jang, T.J.; Kim, K.C.; Cho, H.C.; Seo, J.K. A Fully Automated Method for 3D Individual Tooth Identification and Segmentation in Dental CBCT. *IEEE Trans. Pattern Anal. Mach. Intell.* **2021**, *10*, 6562–6568. [\[CrossRef\]](#)
53. Švábová nee Uhrová, P.; Beňuš, R.; Chovancová nee Kondeková, M.; Vojtušová, A.; Novotný, M.; Thurzo, A. Use of Third Molar Eruption Based on Gambier's Criteria in Assessing Dental Age. *Int. J. Leg. Med.* **2023**. [\[CrossRef\]](#)
54. Thurzo, A.; Strunga, M.; Urban, R.; Surovková, J.; Afrashtehfar, K.I. Impact of Artificial Intelligence on Dental Education: A Review and Guide for Curriculum Update. *Educ. Sci.* **2023**, *13*, 150. [\[CrossRef\]](#)
55. Thurzo, A.; Kurilová, V.; Varga, I. Artificial Intelligence in Orthodontic Smart Application for Treatment Coaching and Its Impact on Clinical Performance of Patients Monitored with AI-Telehealth System. *Healthcare* **2021**, *9*, 1695. [\[CrossRef\]](#) [\[PubMed\]](#)
56. Thurzo, A.; Urbanová, W.; Neuschlová, I.; Paouris, D.; Čverha, M. Use of Optical Scanning and 3D Printing to Fabricate Customized Appliances for Patients with Craniofacial Disorders. *Semin. Orthod.* **2022**, *28*, 92–99. [\[CrossRef\]](#)
57. Caruso, S.; Caruso, S.; Pellegrino, M.; Skafi, R.; Nota, A.; Tecco, S. A Knowledge-Based Algorithm for Automatic Monitoring of Orthodontic Treatment: The Dental Monitoring System. Two Cases. *Sensors* **2021**, *21*, 1856. [\[CrossRef\]](#)
58. Morabito, A.E.; Guardiani, E.; Mandolini, M.; Brunzini, A.; Facco, G.; Mazzoli, A.; Forcelllese, A.; Gigante, A. Comparison of Three 3D Segmentation Software Tools for Hip Surgical Planning. *Sensors* **2022**, *22*, 5242. [\[CrossRef\]](#)
59. Lee, S.; Kim, J.E. Evaluating the Precision of Automatic Segmentation of Teeth, Gingiva and Facial Landmarks for 2D Digital Smile Design Using Real-Time Instance Segmentation Network. *J. Clin. Med.* **2022**, *11*, 852. [\[CrossRef\]](#) [\[PubMed\]](#)
60. Thurzo, A.; Urbanová, W.; Novák, B.; Czako, L.; Siebert, T.; Stano, P.; Mareková, S.; Fountoulaki, G.; Kosnáčová, H.; Varga, I. Where Is the Artificial Intelligence Applied in Dentistry? Systematic Review and Literature Analysis. *Healthcare* **2022**, *10*, 1269. [\[CrossRef\]](#)
61. Artificial Intelligence and Deep Learning in Dental Radiology. Available online: <https://www.oralhealthgroup.com/features/artificial-intelligence-and-deep-learning-in-dental-radiology-a-way-forward-in-point-of-care-radiology/> (accessed on 24 March 2023).

62. 6 Innovative Artificial Intelligence Applications in Dentistry. Available online: <https://www.v7labs.com/blog/ai-in-dentistry> (accessed on 24 March 2023).
63. Albitar, L.; Zhao, T.; Huang, C.; Mahdian, M. Artificial Intelligence (AI) for Detection and Localization of Unobtained Second Mesial Buccal (MB2) Canals in Cone-Beam Computed Tomography (CBCT). *Diagnostics* **2022**, *12*, 3214. [[CrossRef](#)]
64. How Accurate Are Facial Recognition Systems—And Why Does It Matter? | Strategic Technologies Blog | CSIS. Available online: <https://www.csis.org/blogs/strategic-technologies-blog/how-accurate-are-facial-recognition-systems-and-why-does-it> (accessed on 24 March 2023).
65. Chung, E.-J.; Yang, B.-E.; Byun, S.-H.; Yi, S.; Kim, Y.-H.; Kang, S.-H. Effectiveness Of Cone-Beam Computed Tomography (CBCT)-Generated Cephalograms Using Artificial Intelligence (AI) Cephalometric Analysis. *Sci. Rep.* **2022**, *12*, 20585. [[CrossRef](#)] [[PubMed](#)]

**Disclaimer/Publisher's Note:** The statements, opinions and data contained in all publications are solely those of the individual author(s) and contributor(s) and not of MDPI and/or the editor(s). MDPI and/or the editor(s) disclaim responsibility for any injury to people or property resulting from any ideas, methods, instructions or products referred to in the content.